



International Journal of Medical Anesthesiology

E-ISSN: 2664-3774
P-ISSN: 2664-3766
www.anesthesiologypaper.com
IJMA 2020; 3(1): 43-47
Received: 25-11-2019
Accepted: 27-12-2019

Urvashi Yadav
Associate Professor,
Department of
Anaesthesiology, Uttar
Pradesh University of Medical
Sciences, Saifai, Etawah,
Uttar Pradesh, India

Dheer Singh
Professor, Department of
Anaesthesiology, Uttar
Pradesh University of Medical
Sciences, Saifai, Etawah,
Uttar Pradesh, India

Mohammad Shakir
Resident, Department of
Anaesthesiology, Uttar
Pradesh University of Medical
Sciences, Saifai, Etawah,
Uttar Pradesh, India

Corresponding Author:
Dheer Singh
Professor, Department of
Anaesthesiology, Uttar
Pradesh University of Medical
Sciences, Saifai, Etawah,
Uttar Pradesh, India

A randomized controlled study comparing supraclavicular brachial plexus block under guidance of ultrasound and peripheral nerve stimulator

Urvashi Yadav, Dheer Singh and Mohammad Shakir

DOI: <https://doi.org/10.33545/26643766.2020.v3.i1a.69>

Abstract

Background and Aim: The supraclavicular approach is the easiest and most effective approach to for upper limb anaesthesia. We conducted this study to compare USG with PNS in terms of onset and duration of motor and sensory blockade, procedure time, and complications if any.

Study Design: Prospective, randomised, double blind study.

Methodology: Sixty patients over the age of 18 years scheduled for elective upper limb surgery were randomly allocated into two groups. In Group A, under ultrasound guidance, patients got supraclavicular brachial plexus block and PNS was used in Group B patients. As local anaesthetic 25 ml of 0.75% ropivacaine was used in both the groups. Procedure time, onset and duration of sensory and motor block, success rate and complications were accessed.

Results: Mean procedure time was shorter with USG (5.59 ± 1.01 min) compared to PNS (8.77 ± 1.47). The mean onset of sensory block (4.97 ± 0.73 min vs. 7.12 ± 0.86 min) and motor block (7.21 ± 0.77 min vs. 9.42 ± 1.06 min) were considerably shorter in Group A compared to Group B. The mean duration of sensory (294.90 ± 9.79 min vs. 257.12 ± 17.86 min) and motor block (270.21 ± 10.69 vs 235.81 ± 16.16) was significantly prolonged in Group A compared to Group B. Eight patients in group B and one patient in Group A had a vascular puncture identified on aspiration.

Conclusion: We conclude that USG is a safe and effective technique for supraclavicular block in terms of quality and duration with less complications compared to PNS.

Keywords: PNS, supraclavicular brachial block, upper limb surgeries, ultrasound

Introduction

Supraclavicular brachial plexus block can be used as a sole anaesthetic for upper limb orthopaedic surgeries as it provides dense anaesthesia at or distal to elbow with improved postoperative pain relief^[1]. Higher failure rates and complications were connected with the classical method using the anatomical landmark^[2]. Ultrasonographic guidance (USG) and peripheral nerve stimulator (PNS) enhanced the success rate. The peripheral nerve stimulator (PNS) makes it possible to better locate the brachial plexus compared to the blind technique, but it did not decrease the danger of injury to surrounding structures^[3, 4]. Using ultrasonography (USG) to locate the brachial plexus has revolutionized the area of regional anaesthesia. It provides visualization of anatomical structures and needle movement in real time and has reduced rates of complication. However, USG machine is expensive and requires expertise^[5]. We conducted this study in order to compare the above two methods in terms of procedure time, block features and complication rates.

Methods

This prospective, randomized study was performed on 60 American Society of Anesthesiologists (ASA) Grade I/II patients of either sex from 18 to 60 years of age, admitted for elective upper limb surgery. Institutional Ethics Committee approval was obtained before commencement of study and informed consent was taken from all patients. Exclusion criteria were presence of coagulopathy, injection site infection, local anesthetic allergy, severe pulmonary pathology, and mental incapacity precluding informed consent, a body mass index more than 35, or preexisting neuropathy in the operative limb.

A sample size of 25 patients per group was calculated to detect a 5-minute difference in the onset of block with type 1 error (alpha) of 0.05 and type 2 error (beta) of 0.80. We included 30 patients in each group to compensate for possible dropouts. We used computer derived sequence of numbers for randomization and sealed envelope method for group distribution.

In operation theatre minimum mandatory monitoring started and iv line was secured. All patients received premedication intravenously (0.03 mg/kg) midazolam.

The patient's head was turned away from the side of block in supine position. Senior consultant who was not engaged in data collection conducted the block in both groups.

Using a mobile ultrasound system (sonosite M-Turbo, Sonosite inc. bothell, WA, USA) with a 38 mm 8-13 MHz linear frequency ultrasound transducer (HFL-38), supraclavicular brachial plexus block was conducted under USG supervision in Group A. Probe was placed over the lateral part of supraclavicular fossa in the coronal oblique plane and subclavian artery was recognized. Subclavian artery appears as an anechoic, hypodense, pulsatile and non-compressible round structure. Color Doppler can further confirm the artery. Brachial plexus appears as a cluster of hypoechoic "grape-like" structures superolateral to subclavian artery. A 22 G needle connected to a three-way extension was inserted through the skin after skin infiltration with 2% lignocaine. It was progressed slowly towards the sheath of the brachial plexus under vision, with the subclavian artery as the landmark. Two ml of saline was injected to observe the spread and when the spread was found to be satisfactory, the local anesthetic solution 25 ml of 0.75% ropivacaine was injected into the sheath under vision in at least two different needle positions around the subclavian artery after negative aspiration.

In group B, the positive PNS electrode (Fisher & Paykel innervator) was attached to an ECG lead and placed in the ipsilateral shoulder and the negative electrode was attached to an isolated needle (Pajunk sonoplex stimulating cannula) of 22 G nerve stimulator. The subclavian artery was palpated in the supraclavicular area after skin preparation and 2% of lignocaine was infiltrated at the insertion site of the needle. The needle was further advanced in a downward and inward direction with the PNS set to deliver 1.5–2.5 mA current at 1 Hz frequency and 0.1 ms of pulse duration until it comes in vicinity of lower trunk, which is manifested by a twitch of the fingers in either flexion or extension. The current was gradually reduced to 0.5 mA as the finger twitch was identified, and then the local anesthetic solution (25 ml of 0.75% ropivacaine) was injected after negative aspiration. A blind observer recorded the onset and duration of sensory and motor block at 5 min interval for 30 min. The procedure

time was taken as time interval from the first needle insertion to its removal at the end of the block. Sensory evaluation for pain and touch was performed for the entire cutaneous innervation of upper limb by using the following three-point scale. (• 2 - normal sensation • 1 - hypoesthesia • 0 - no sensation felt). The time from removing the block needle to the time when a score of zero has been achieved was taken as onset time of sensory block. Motor block was assessed according to modified Bromage scale for upper extremities [6]. Flexion, extension, abduction, adduction was checked at the elbow, wrist, and fingers. The time from the removing the block needle to the time when modified Bromage grade of 3/4 has been achieved was taken as onset time for motor block. Grading of Modified Bromage grade used was as follows:

1. Grade 0: full extension of elbow, wrist, and fingers that means normal motor function.
2. Grade 1: Able to flex and extend both wrist and fingers
3. Grade 2: Able to flex and extend only the fingers
4. Grade 3: Unable to move elbow, wrist, and fingers that means complete motor block.

Mild sedation (iv Midazolam 1–2 mg) was administered to all patients during the surgery. In case of inadequate analgesia, supplementation with iv fentanyl 1 mcg.kg⁻¹ was provided. If pain was still perceived by the patient, then general anesthesia was given, and such cases was excluded from the analysis. Post-operatively, all patients were monitored for 1 h and then discharged to their ward. Intraoperative supplementary analgesic requirement, block failure and adverse effects if any were noted. Postoperative pain was accessed by a 10-point visual analog scale (0 = no pain and 10 = worst imaginable pain) and a score of more than 3 was taken as duration endpoint of the block.

Statistical analysis

Data statistical analysis was conducted using SPSS version 20 (IBM, Armonk, NY). Data were displayed in mean and standard deviation for continuous variables and numbers (percentage) for categorical variables. Independent t-test were used to compare the mean between the groups and Chi-square test for categorical variables. Statistically $P < 0.05$ was regarded significant.

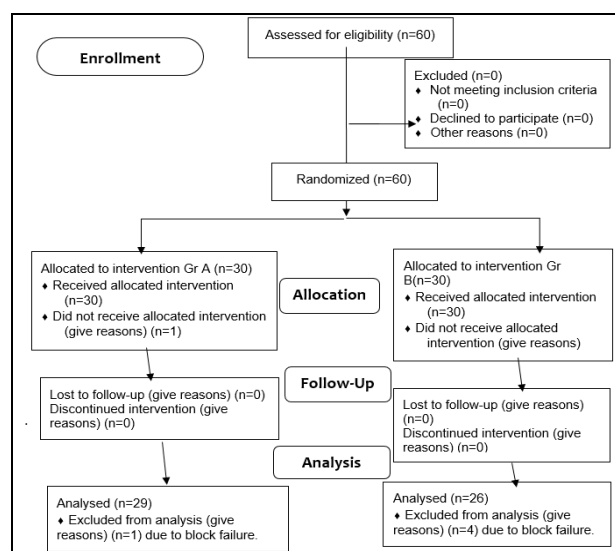


Fig 1: Consort Flow Diagram.

Results

Total sixty patients were recruited for the study and five were excluded due to block failure as shown in consort chart [Figure-1]. The mean age, gender, BMI, ASA physical state

and duration of surgery were comparable in both the groups, and the P value between the groups was <0.05 , i.e., statistically insignificant [Table 1]. The pain score was similar between the two groups [Figure-2].

Table 1: Comparison of demographic profile and intraoperative characteristics of patients between two groups.

Parameters	Group A (n=29)	Group B (n=26)	P value
Age (years)	34.55±12.82	35.38±10.65	0.77
Male/Female	22/7	17/9	0.39
BMI(Kg.m ²)	21.10±2.78	21.60±4.09	0.59
Duration of surgery (min)	137.83±31.01	140.62±36.23	0.760
Procedure time (min)	5.59±1.01	8.77±1.47	0.001*
Onset of sensory block (min)	7.21±0.77	9.42±1.06	0.001*
Duration of Sensory (min)	294.90±9.79	257.12±17.86	0.001*
Duration of Motor(min)	270.21±10.69	235.81±16.16	0.001*
Block failure rate	1/30(3.33%)	4/30(13.33%)	0.16
Vascular Puncture	1	8	0.001*

As shown in [Table 1], In Group A, the mean procedure time was considerably lesser than in Group B (5.59±1.01 versus 8.77±1.47 min). The onset of sensory block in Group A was earlier than in Group B (4.97±0.73 versus 7.12±0.86 min), and the difference was statistically significant. The onset of motor block was 7.21±0.77 min in Group A and 9.42±1.06 min in Group B and was statistically significant ($P<0.001$). The mean duration of sensory block was significantly higher in Group A compared to Group B (294.90±9.79min vs. 257.12±17.86 min) [Table 1]. The mean duration of the motor block was significantly different between the two groups (270.21±10.69 in group A vs 235.81±16.16 in group B). The requirement of intravenous

fentanyl supplementation was not significantly different. In Group B out of 30 patients, 4 patients needed conversion to general anesthesia compared to 1 patient in Group A, although this was not statistically significant. [Table-1] Eight patients (26.66%) had a vascular puncture in group B that was verified by a flash of blood in the syringe on aspiration while One patient (3.33%) in Group A had a vascular puncture detected on aspiration prior to injection of the drug and the difference was statistically significant ($P<0.001$). There were no neurological complications, pneumothorax, and local anesthetic toxicity in either group of patients.

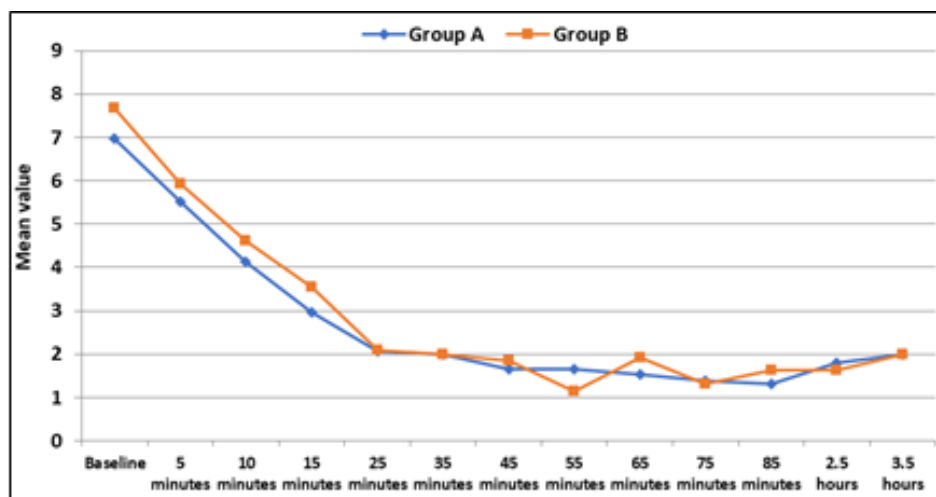


Fig 2: Comparison of Visual Analog Scale for pain between two groups across the time periods.

Discussion

This study shows that US allowed the drug to be delivered more accurately at the brachial plexus in real-time under direct vision. This led to statistically significant number of effective blocks of higher quality and intensity. In Group A, the average block execution time was considerably shorter than in Group B in present study, It is similar to Thomas *et al.*, who compared ultrasound guided interscalene block to nerve stimulation in residency training programs and noted considerably shorter procedure time in USG group compared to PNS group (4.3±1.5 vs. 10 ± 1.5 min, respectively) [13]. Similarly, Williams *et al.* and Alfred *et al.* observed a significantly shorter time to perform the block with USG compared to PNS [7, 8]. However, Shivender Singh

et al concluded that that there was scope of learning and improving upon US-guided nerve blocks as the operator became more familiar with the technique which was not the same with the technique of nerve stimulation. This study advocates the fact that more expert person can put ultrasound guided block faster than the less conversant person [9]. This difference could be explained by the fact that with USG, needle is placed under direct vision whereas repeated needle pricks and repositioning are ultimately required in the PNS technique.

The mean onset time for sensory and motor block was discovered to be considerably shorter in Group A (4.97±0.73 min and 7.21±0.77 min, respectively) relative to Group B (7.12±0.86 min and 9.42±1.06 min, respectively).

This is similar to the study conducted by Ratnawat *et al.* in which time of onset of sensory and motor block in USG group was significantly shorter than in the PNS group [10]. Shivender Singh *et al.*, also found similar results [9]. However, our results were contrary to the research conducted by Duncan *et al.*, in which the onset time of sensory and motor block was comparable between the USG and PNS groups [11]. The mean duration of sensory and motor block was considerably longer in Group A (294.90 ± 9.79 and 270.21 ± 10.69 min, respectively) relative to Group B (257.12 ± 17.86 and 235.81 ± 16.16 min, respectively). The findings of present study are comparable to those of Alfred *et al.* who observed a considerably extended duration of sensory and motor block in USG group (8.0 ± 0.89 h and 6.03 ± 0.75 h respectively) compared to PNS group (7.25 ± 1.42 h and 5.5 ± 1.31 h, respectively) [7]. and Singh *et al.* also observed a prolonged block with USG. Our findings are contrary to Duncan *et al.*, in which both the USG and PNS groups had comparable mean duration of sensory and motor block using 1:1 mixture of 0.5% bupivacaine and 2% lignocaine with adrenaline [11].

The ultrasound guided supraclavicular block helps to evaluate the precise depth and location along with the anatomy of the neighboring structures, thus helping to place the needle accurately and depositing the local anesthetic inside the sheath of the nerve. This hastens the onset of the block and may explain the prolonged duration of block seen in our study. In our study, four patients in Group B (13.33%) compared to one patients in Group A (3.33%) out of thirty required conversion to general anesthesia that was not discovered to be statistically significant ($P = 0.16$) [Table - 1]. In study by Singh *et al.* 10% of patients needed conversion to general anaesthesia with USG, compared with 27.9% in PNS required additional nerve blocks ($P = 0.028$) [9]. A similar success rate for successful block was observed in Williams *et al.* and Duncan *et al.* in both groups [8, 11]. Jeon and Kim reported that success rates were 93.7% and 75.0% respectively, when a distal response and proximal reaction were noted with PNS for supraclavicular block [12]. Eight patients in group B and one patient in Group A had a vascular puncture detected on aspiration prior to injection of the drug and the difference was statistically significant ($P < 0.001$). Present study is in accord with Shivender Singh *et al.* who reported seven vascular punctures in the PNS category, with only one being in the USG group during check aspiration [9]. Several studies have shown nil or lesser incidence of complications with the use of USG as it helps in direct visualization of the needle with relation to the cervical pleura thereby avoiding the puncture of pleura and development of pneumothorax [14, 17].

Limitation

The small sample size is one of the constraints of this study. To access and compare the occurrence of complications such as arterial puncture and pneumothorax, a multicentric survey with a big sample size is needed. Our research did not record the number of needle pricks and needle readjustments that will help to evaluate patient discomfort and satisfaction.

Conclusion

Using ultrasound guided technique, Supraclavicular brachial plexus block has less block execution time, a quicker onset, long duration of sensory and motor block with less block

failure rate and less complications compared to an equivalent dose by nerve stimulator technique. We suggest that ultrasound guided blocks can be preferred over nerve stimulator guided blocks.

References

- Pande R, Pande M, Bhadani U, Pandey CK, Bhattacharya A. Supraclavicular block as sole anesthetic techniques. *Anaesthesia*. 2000; 55(8):798-802.
- Carty S, Nicholls B. Ultrasound-guided regional anaesthesia. *Continuing Education in Anaesthesia Critical Care & Pain*. 2007; 1:20-4.
- Fanelli G, Casati A, Garancini P, Torri G. Nerve stimulator and multiple injection technique for upper and lower limb blockade: Failure rate, patient acceptance, and neurologic complications. *Study Group on Regional Anesthesia. Anesth Analg*. 1999; 88:847-52.
- Brown DL, Cahill DR, Bridenbaugh LD. Supraclavicular nerve block: Anatomic analysis of a method to prevent pneumothorax. *Anesth Analg*. 1993; 76:530-4.
- Chan VW, Perlas A, Rawson R, Odukoya O. Ultrasound-guided supraclavicular brachial plexus block. *Anesth Analg*. 2003; 97:1514-7.
- Gaumann D, Forster A, Griessen M, Habre W, Poinot O, Della Santa D *et al.* Comparison between clonidine and epinephrine admixture to lidocaine in brachial plexus block. *Anesth Analg*. 1992; 75:69-74.
- Alfred VM, Srinivasan G, Zachariah M. Comparison of USG with PNS guide technique for supraclavicular block in upper limb surgery. *Anaesth Essays Res*. 2018; 12:50-4.
- Williams SR, Chouinard P, Arcand G, Harris P, Ruel M, Boudreault D *et al.* Ultrasound guidance speeds execution and improves the quality of supraclavicular block. *Anesth Analg*. 2003; 97:1518-23.
- Singh S, Goyal R, Upadhyay Navdeep KK, Sethi N, Sharma MR, Sharma A *et al.* Evaluation of brachial plexus blocks using a nerve stimulator versus ultrasound guidance: A randomized control trial. *Journal of Anesthesiology Clinical Pharmacology*. 2015; 31:370-4.
- Ratnawat A, Bhati FS, Khatri C, Srinivasan B, Sangwan P, Chouhan DS *et al.* Comparative study between nerve stimulator guided technique and ultrasound guided technique of supraclavicular nerve block for upper limb surgery. *Int J Res Med Sci*. 2016; 4:2101-6.
- Duncan M, Shetti AN, Tripathy DK, Roshansingh D, Krishnaveni N. A comparative study of nerve stimulator versus ultrasound-guided supraclavicular brachial plexus block. *Anesth Essays Res*. 2013; 7:359-64.
- Jeon DG, Kim WI. Comparison of a supraclavicular block showing upper arm twitching response with a supraclavicular block showing wrist or finger twitching response. *Korean J Anesthesiol*. 2010; 58:464-7.
- Thomas LC, Graham SK, Osteen KD. To compare ultrasound and nerve stimulation technique for interscalene brachial plexus block for shoulder surgery. 2012; 12(1):86.
- Krutika BR, Birva NK, Veena RS. Ultrasonography

- guided technique offer advantage over peripheral nerve stimulator guided technique in supraclavicular brachial plexus block. *Anesthesiology*. 2013; 3(3):241-4.
15. Kumar A, Sharma DK, Sibi EM, Gogoi B. Peripheral nerve stimulator vs ultrasound guided axillary block using multiple injection technique. *Indian journal of anaesthesia*. 2014; 58(6):700-4.
 16. Mehta SS, Shah SM. Comparative study of supraclavicular brachial plexus block by nerve stimulator vs ultrasound guided method. *NHL Journal of Medical Sciences*, 2015, 49-52.
 17. Liu GY, Chen ZQ, Jia HY, Dai ZG, Zhang XJ. The technique comparison of brachial plexus blocks by ultrasound guided with blocks by nerve stimulator guided. *Int J Clin Exp Med*. 2015; 8(9):16699-703.