



# International Journal of Medical Anesthesiology

E-ISSN: 2664-3774  
P-ISSN: 2664-3766  
[www.anesthesiologypaper.com](http://www.anesthesiologypaper.com)  
IJMA 2018; 1(2): 01-03  
Received: 01-05-2018  
Accepted: 05-06-2018

**Dr. Syed Hakim**  
Department of Anesthesia,  
Enam Medical College &  
Hospital, Bangladesh

## Conventional & the simple pre-determined length insertion technique (SPLIT) of tracheal intubation: A comparative study

**Dr. Syed Hakim**

DOI: <https://doi.org/10.33545/26643766.2018.v1.i2a.6>

### Abstract

**Background:** The most common cause of mortality and serious morbidity due to anaesthesia is from airway problems. The present study compared conventional and the simple pre-determined length insertion technique (SPLIT) of tracheal intubation.

**Materials & Methods:** The present study was conducted on 84 patients with age between 18 and 60 years with American Society of Anesthesiologists physical status 1 and 2 scheduled for an elective surgical procedure requiring general anaesthesia. Patients were divided into 2 groups of 42 each. In group I patients, conventional flexible fiberoptic laryngoscopy was done followed by SPLIT and vice versa in group II. The time taken from the introduction of fiberscope from the incisors to the visualization of glottis (T1), time taken from the visualization of glottis to the passage of fiber-optic tip just beyond glottis (T2), time from the incisors to pass it beyond the glottis (T3), pre-determined length, vital parameters were recorded.

**Results:** Out of 84 patients, males were 30 and females were 54. T1 in group I was 14.5 and in group II was 11, T2 in group I was 12.7 and in group II was 8.4, T3 in group I was 22.6 and in group II was 19.3 seconds. The difference was significant ( $P < 0.05$ ).

**Conclusion:** SPLIT technique found better as compared to conventional technique of tracheal intubation.

**Keywords:** Airway, SPLIT, tracheal intubation

### Introduction

The most common cause of mortality and serious morbidity due to anaesthesia is from airway problems. It is estimated that about one-third of all anaesthetic deaths are due to failure to intubate and ventilate<sup>[1]</sup>. The flexible fiberoptic endoscope is the most valuable single tool available for the anesthesiologist to manage the difficult airway. The flexible fiber-optic bronchoscopy (FOB) guided tracheal intubation remains the gold standard in difficult airway management in spite of many newer airway gadgets<sup>[2]</sup>. FOB-guided intubation can be performed through nasal or oral route either in awake or anaesthetized patients. The actual fiber-optic intubation procedure could be divided into three steps which include the visualization of the glottis with fiberscope, passing the fiberscope through the glottis into trachea till carina and railroading the endotracheal tube over the fiberscope into the trachea<sup>[3]</sup>.

The use of fiberoptic instruments to help in airway management is a relatively a recent event. In 1967, Dr. P. Murphy was the first to use a fiberoptic instrument for the control of airway when he performed a nasal intubation under general anaesthesia for a patient with advanced still's disease using choledochoscope. For successful visualization of the glottis, different methods such as jaw thrust, lingual traction, fiber-optic assisting airway devices and laryngoscopy assisted fiber-optic intubation have been employed<sup>[4]</sup>. The present study compared conventional and the simple pre-determined length insertion technique (SPLIT) of tracheal intubation.

### Materials and Methods

The present study was conducted in the department of Anesthesiology. It comprised 84 patients with age between 18 and 60 years with American Society of Anesthesiologists physical status 1 and 2 scheduled for an elective surgical procedure requiring general anaesthesia. All were informed regarding the study. Ethical approval was obtained from institute prior to the study. General information such as name, age, gender etc. was recorded.

**Corresponding Author:**  
**Dr. Syed Hakim**  
Department of Anesthesia,  
Enam Medical College &  
Hospital, Bangladesh

Patients were divided into 2 groups of 42 each. In group I patients, conventional flexible fiberoptic laryngoscopy was done followed by SPLIT and vice versa in group II. The time taken from the introduction of fiberscope from the incisors to the visualization of glottis (T1), time taken from the visualization of glottis to the passage of fiber-optic tip just beyond glottis (T2), time from the incisors to pass it beyond the glottis (T3), pre-determined length, vital parameters were recorded. Results thus obtained were subjected to statistical analysis. P value less than 0.05 was considered significant.

## Results

**Table 1:** Distribution of patients

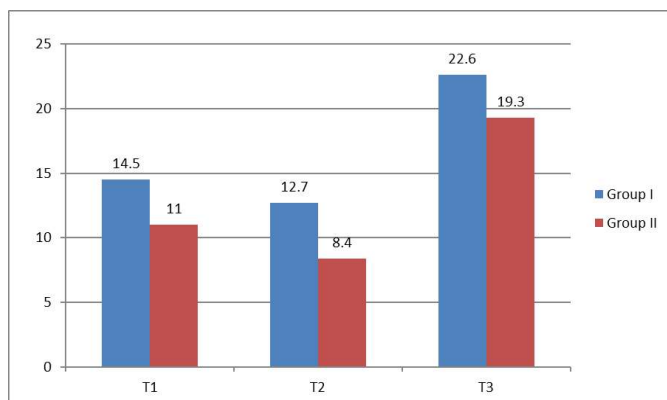
Total- 84		
Gender	Males	Females
Number	30	54

Table 1 shows that out of 84 patients, males were 30 and females were 54.

**Table 2:** Comparison of parameters

Time (Seconds)	Group I	Group II	P value
T1	14.5	11.0	0.05
T2	12.7	8.4	0.01
T3	22.6	19.3	0.01

Table 2 shows that T1 in group I was 14.5 and in group II was 11, T2 in group I was 12.7 and in group II was 8.4, T3 in group I was 22.6 and in group II was 19.3 seconds. The difference was significant ( $P < 0.05$ ).



**Graph I:** Comparison of parameters

## Discussion

Flexible fiberoptic bronchoscopy is very useful for the anesthesiologist in the management of difficult tracheal intubations, evaluation of the upper airway, verification of endotracheal tube placement, repositioning or checking patency of endotracheal tubes, changing endotracheal tubes, placement of double lumen tubes and placement of endobronchial blockers [5]. The flexible fiberoptic intubation bronchoscope gives the competent practitioner the unparalleled opportunity to secure almost any difficult airway encountered. The oral fiber-optic intubation is further demanding than the nasal route because of the perpendicular alignment of oral and pharyngeal axis [6]. The present study compared conventional and the simple pre-determined length insertion technique (SPLIT) of tracheal intubation.

In this study, out of 84 patients, males were 30 and females were 54. T1 in group I was 14.5 and in group II was 11, T2 in group I was 12.7 and in group II was 8.4, T3 in group I was 22.6 and in group II was 19.3 seconds. The difference was significant ( $P < 0.05$ ).

The fiberoptic scope is a flexible instrument, which is capable of transmitting an image from the distal tip to the proximal end. The motion of the tip of the fiberscope can be controlled which enables the operator to direct the scope in any desired fashion. The combined characteristics of controllability, flexibility and image transmission permit anesthesiologists to employ the fiberscope as an aid to tracheal intubation and as a therapeutic instrument [7].

Muthukumar *et al.* [8]. Conducted a randomized controlled study designed to evaluate the simple pre-determined length insertion technique (SPLIT) during oral FOB. Fifty-eight patients were randomized into Group C and Group P. The T1 was significantly less in SPLIT as compared to conventional technique (13 [10, 20.25] vs. 33 [22, 48] s). The T3 was significantly less in SPLIT (24.5 [19.75, 30] vs. 44 [34, 61.25] s). The T1 by SPLIT was comparable between residents and consultants whereas it was significantly more among residents than the conventional technique. The SPLIT was preferred by 91.3% anesthesiologists.

The optical characteristics of fine glass strands are what make fiberoptic technology possible. When glass rods are heated and stretched to diameters of 8 to 25  $\mu$ m, a flexible fiber capable of transmitting light is formed. By comparison, a human hair is approximately 20  $\mu$ m. Light that enters the distal end of the fiber is reflected off the walls until it emerges at the proximal end. To keep a fraction of the light from being lost during transmission, the fiber is clad in a layer of glass that has a different optical density. This process results in total internal reflection of light entering the fiber [9].

## Conclusion

SPLIT technique found better as compared to conventional technique of tracheal intubation.

## References

1. Stacey MR, Rassam S, Sivasankar R, Hall JE, Latto IP. A comparison of direct laryngoscopy and jaw thrust to aid fiberoptic intubation. *Anaesthesia*. 2005; 60:445-8.
2. Wheeler M, Roth AG, Dsida RM, Rae B, Seshadri R, Sullivan CL, *et al.* Teaching residents pediatric fiberoptic intubation of the trachea: Traditional fiberscope with an eyepiece versus a video-assisted technique using a fiberscope with an integrated camera. *Anesthesiology*. 2004; 101:842-6.
3. Mohammadzadeh A, Haghghi M, Naderi B, Chaudhry A, Khan ZH, Rasouli MR, *et al.* Comparison of two different methods of fiber-optic nasal intubation: Conventional method versus facilitated method (NASAL-18). *Ups J Med Sci*. 2011; 116:138-41.
4. Greenberg RS. Facemask, nasal, and oral airway devices. *Anesthesiol Clin North America*. 2002; 20:833-61.
5. Mendes Neto JA, Pinna BR, Caporrino Neto J, Pedrosa JE. Comparison between telelaryngoscopy and suspension laryngoscopy in the diagnosis of benign vocal fold lesions. *Braz J Otorhinolaryngology*. 2008; 74:869-75.

6. Ponka D, Baddar F. Indirect laryngoscopy. *Can Fam Physician*. 2013; 59:1201.
7. Erb T, Hampl KF, Schürch M, Kern CG, Marsch SC. Teaching the use of fiberoptic intubation in anesthetized, spontaneously breathing patients. *Anesth Analg*. 1999; 89:1292-5.
8. Muthukumar E, Elakkumanan LB, Bidkar PU, Satyaprakash M, Mishra SK. Evaluation of simple pre-determined length insertion technique (SPLIT) with conventional method for oral fibreoptic intubation: A randomised cross-over study. *Indian J Anaesth*. 2017; 61:36-41.
9. Rosenblatt W, Ianus AI, Sukhupragarn W, Fickenscher A, Sasaki C. Preoperative endoscopic airway examination (PEAE) provides superior airway information and may reduce the use of unnecessary awake intubation. *Anesth Analg*. 2011; 112:602-7.