



# International Journal of Medical Anesthesiology

E-ISSN: 2664-3774  
P-ISSN: 2664-3766  
[www.anesthesiologypaper.com](http://www.anesthesiologypaper.com)  
IJMA 2020; 3(2): 96-101  
Received: 16-01-2020  
Accepted: 18-02-2020

**HS Prajwal Patel**  
Department of Anaesthesia,  
Adichunchanagiri Institute of  
Medical Sciences, Mandya,  
Karnataka, India

**Sarvesh B**  
Department of Anaesthesia,  
Adichunchanagiri Institute of  
Medical Sciences, Mandya,  
Karnataka, India

**BT Shivaramu**  
Department of Anaesthesia,  
Adichunchanagiri Institute of  
Medical Sciences, Mandya,  
Karnataka, India

**Corresponding Author:**  
**HS Prajwal Patel**  
Department of Anaesthesia,  
Adichunchanagiri Institute of  
Medical Sciences, Mandya,  
Karnataka, India

## A clinical study of effects of clonidine as adjuvant with ropivacaine in ultrasound guided axillary brachial plexus block

**HS Prajwal Patel, Sarvesh B and BT Shivaramu**

**DOI:** <https://doi.org/10.33545/26643766.2020.v3.i2b.129>

### Abstract

**Background:** Axillary Brachial plexus block is the distal block performed on the brachial plexus. With the advent of ultrasound guidance establishing the blockade has been easier with reduced drug dosage and less complications.

**Objective:** To evaluate and compare the effects of addition of clonidine with ropivacaine for axillary block with reference to a) onset of sensory blockade b) onset of motor blockade c) duration of analgesia.

**Methods:** 60 patients of ASA class 1 & 2 for upper limb surgical procedures were randomly allocated into two groups of 30 each, Group P will receive ropivacaine 0.75% 20ml + NaCl 0.9% (0.5ml) Group D will receive ropivacaine 0.75% 20ml + clonidine 75µg (0.5ml). With ultrasound guidance axillary brachial plexus block was administered. Testing for onset of sensory blockade was done using pin prick method, Motor block was assessed using modified Bromage scale, Post operatively patients would be assessed for the duration of sensory and motor blockade.

**Results:** The present study shows that 20 ml of 0.75% Ropivacaine with clonidine 75 mcg prolonged the duration of motor, sensory block and duration of analgesia when compared with 20 ml of 0.75% Ropivacaine with NaCl 0.9%. The onset of sensory, motor blocks was significantly faster with 0.75% Ropivacaine with clonidine 75 mcg group (Group D) when compared with 0.75% Ropivacaine with NaCl 0.9% group (Group P).

**Conclusion:** Clonidine 75 µg as an adjuvant to 0.75% ropivacaine produces satisfactory onset of sensory and motor blockade, with increased duration of analgesia when used for axillary brachial plexus block under ultrasound guidance without any adverse effects.

**Keywords:** clonidine, ropivacaine, ultrasound, axillary brachial plexus block

### Introduction

Regional Anaesthesia in the form of brachial plexus block [1] is often used for orthopaedic surgeries of the upper limb. It is often used either as an adjuvant to general anaesthesia or as the primary method of anaesthesia. The axillary approach to the brachial plexus is the most popular because of its ease, reliability and safety. Blockade occurs at the level of terminal nerves [2].

The use of ultrasound has gained popularity in the field of regional anaesthesia, as it has many advantages over the conventional technique of nerve stimulation. It provides a direct visualization of the anatomic structures and helps in minimizing vascular punctures by allowing a dynamic vision of the needle advancement and local anaesthetic spread. It has also been shown to reduce the number of needle redirections, to avoid multiple pricks and to enhance block success rates when performing axillary brachial plexus blocks.

The use of ultrasound has facilitated the use of low doses because needle placement and spread of the injectate as guided by ultrasound reduce the amount of local anaesthetic needed for peripheral nerve block.

Ropivacaine is a long acting amide local anaesthetic [3]. It is less lipophilic than bupivacaine, which accounts for its decreased central nervous system toxicity and cardiotoxicity. Hence, an attempt has been made in this study.

Clonidine is commonly used as an adjuvant to local anaesthetics in peripheral nerve blocks where it prolongs the duration of anesthesia as well as analgesia. This effect is obtained at relatively small dosages (75-150 µg) which obviously reduce the risk of side effects.

Adding Clonidine gives very good quality of analgesia after upper limb surgery with the duration of analgesia lasting beyond 24 hours. Clonidine thus has wide applications as an adjunct to local anaesthetic in peripheral regional blocks [4, 5].

The present study of axillary brachial plexus block using ultrasound<sup>6</sup> compares the effects of Ropivacaine alone and Ropivacaine-Clonidine combination. The effects on postoperative analgesia and associated adverse effects are also compared between the two groups.

### Materials and Method

A prospective randomized double blind study is planned. 60 patients of ASA I and II physical status aged 18-45yrs will be scheduled to undergo elective upper limb surgical procedures. They will be randomly allocated into two groups by computer generated randomization into Group P will receive ropivacaine 0.75% 20ml + NaCl 0.9% (0.5ml) Group D will receive ropivacaine 0.75% 20ml + clonidine 75µg (0.5ml)

### Inclusion criteria:

- Age group between 18-45yrs
- ASA I and II
- Patients with body weight of 50-80kgs
- Who gives informed written consent

### Exclusion criteria;

- Patients not willing to give informed consent
- Unco-operative patients
- Local pathology at the site of injection
- History of bleeding disorders, convulsions, severe neurological deficit and allergy
- History of major organ system illness (cardiac, respiratory, hepatic and renal failure)

### Methodology

After obtaining approval and clearance from the institutional ethical committee, the patients fulfilling the inclusion criteria will be enrolled for the study after obtaining informed consent.

Patients admitted for upper limb surgical procedures will be taken up for the study.

All the patients will undergo pre anaesthetic evaluation and routine necessary investigations will be carried out. Patients coming under ASA I and II category would be explained about the procedure in detail.

A total of 60 no of patients will be randomly allocated into two groups of 30 each

Group P will receive ropivacaine 0.75% 20ml + NaCl 0.9% (0.5ml) Group D will receive ropivacaine 0.75% 20ml + clonidine 75µg (0.5ml)

All the patients will be prescribed 0.5mg of alprazolam and 150mg of ranitidine orally to be taken on the night before surgery. Patients will also be advised to be nil orally from 10pm onward on the night before surgery.

Ensuring overnight NPO status, on arrival in the OT, patient will be placed in supine position on OT table and monitors will be connected HR, NIBP, ECG and SPO<sub>2</sub> will be recorded as per standard ASA guidelines. Premedication which includes injection midazolam 0.04mg/kg iv would be administered after obtaining an IV access with 18G catheter. Patients arm is abducted to 90°. Under aseptic precautions

with ultrasound guidance, median nerve, ulnar nerve and radial nerve which lie at 11°clock, 2°clock and 6°clock position respectively in relation to axillary artery will be identified. Musculocutaneous nerve which is slightly lateral and between biceps and coracobrachialis will be marked. Injection of drug into the neurovascular sheath will be done after ensuring needle position inside the sheath using in-plane method.

Testing for onset of sensory blockade will be done using pin prick method, the assessment will be made every 1 minute thereafter till patients feels no pain to pinprick. Motor block will be assessed using modified Bromage scale. After the surgical procedure patients would be assessed for the duration of sensory and motor blockade and the time noted. Assessment of sensory blockade will be on VAS scale. Cessation of analgesia is taken at the time when the patient asks for rescue analgesia. Any untoward effects during the procedure will be noted down.

### Scoring Systems

#### Sensory block

The sensory block will be assessed by pin prick with 25 gauge needle.

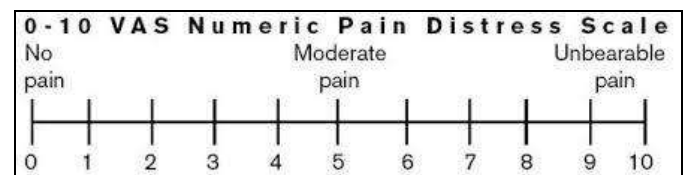
#### Sensory Block

- Sharp pain
- Touch sensation only
- Not even touch sensation

#### Pain rating scale

##### Visual analogue scale

A simple assessment tool consisting of a 10 cm line with 0 on one end, representing no pain, and 10 on the other, representing the worst pain ever experienced, with a patient marks to indicate the severity of his or her pain



#### Motor block

##### Modified Bromage scale

- 0 - Able to raise the extended arm to 90° for a full 2 secs
- 1 - Able to flex the elbow and move the fingers but unable to raise the extended arm.
- 2 - Unable to flex the elbow but able to move the fingers
- 3 - Unable to move the arm, elbow or fingers

Onset of motor blockade will be considered when there will be Grade 1 motor blockade. Peak motor block will be considered when there will be Grade 3 motor blockade.

#### Statistical Analysis

Statistical analysis of data will be done using student t test (z test) for parametric data. Non parametric data will be analyzed by Chi-square test. Statistical significance was considered if P value < 0.05

#### Results and Observation

No statistical significance was found in demographic profile of age, sex and weight, thereby making the two groups similar and comparable.

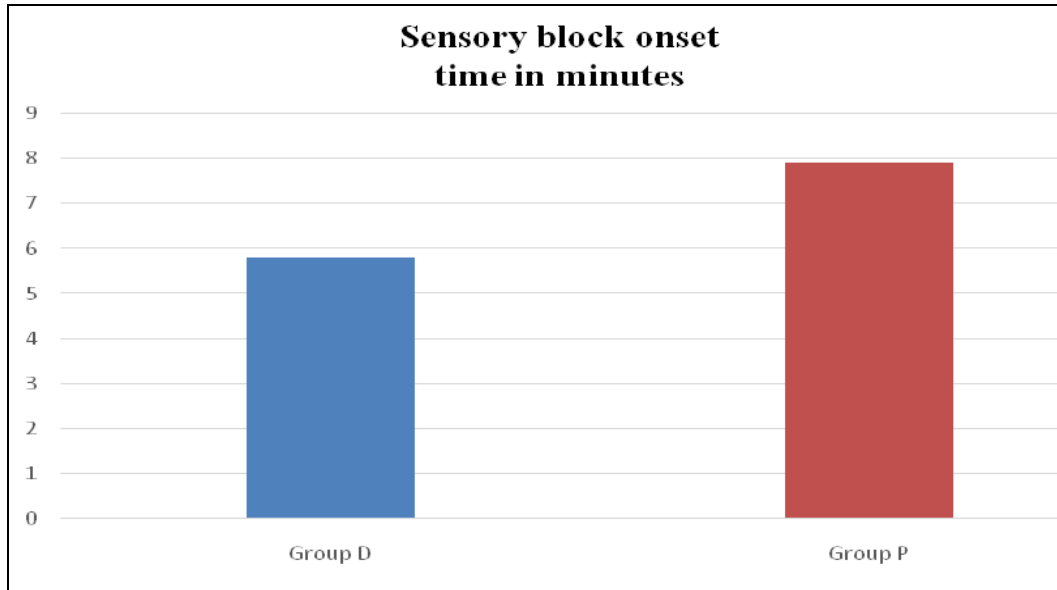
**Block Characteristics**

**Onset of sensory block**

The onset of sensory block in group D was  $5.80 \pm 0.847$  minutes, and in group P the onset of sensory block was in  $7.93 \pm 0.907$  minutes. The difference between the two groups in terms of sensory block onset was statistically significant.  $p$  value  $< 0.001$ .

**Table 1: Onset of sensory block**

	<b>Group D Mean <math>\pm</math> SD</b>	<b>Group P Mean <math>\pm</math> SD</b>	<b>P- Value</b>
Sensory block onset time in minutes	5.80 $\pm$ 0.847	7.93 $\pm$ 0.907	0.001



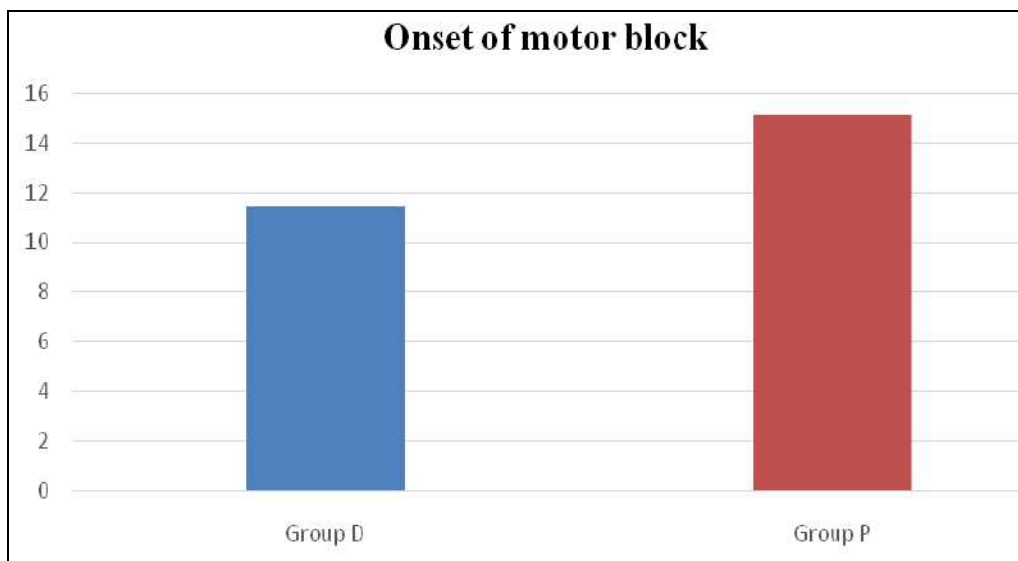
**Graph 1: Onset of sensory block**

**Onset of motor block**

The onset of motor block in group D was  $11.43 \pm 1.569$  minutes, and in group P the onset of motor block was in  $15.10 \pm 2.771$  minutes. The difference between the two groups in terms of motor block onset was statistically significant.  $p$  value  $< 0.001$ .

**Table 2: Onset of motor block**

	<b>Group D Mean <math>\pm</math> SD</b>	<b>Group P Mean <math>\pm</math> SD</b>	<b>P- Value</b>
Motor block onset time in minutes	11.43 $\pm$ 1.569	15.10 $\pm$ 2.771	0.001



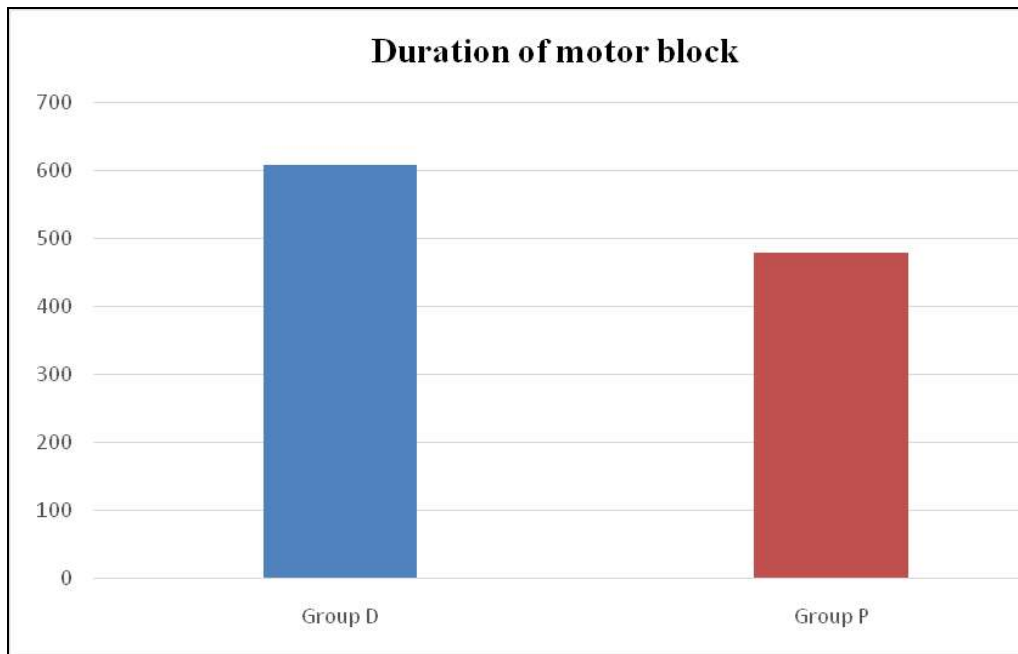
**Graph 2: Onset of motor block**

**Duration of Motor Block**

Table 3 shows that the motor block lasted for  $607.47 \pm 4.041$  minutes in group D and  $479.03 \pm 10.118$  minutes in group P, with the difference between the two groups being statistically significant.  $P$  value  $< 0.001$ .

**Table 3: Duration of motor block**

	<b>Group D Mean <math>\pm</math> SD</b>	<b>Group P Mean <math>\pm</math> SD</b>	<b>P- Value</b>
Duration of Motor block in minutes	607.47 $\pm$ 4.041	479.03 $\pm$ 10.12	0.001



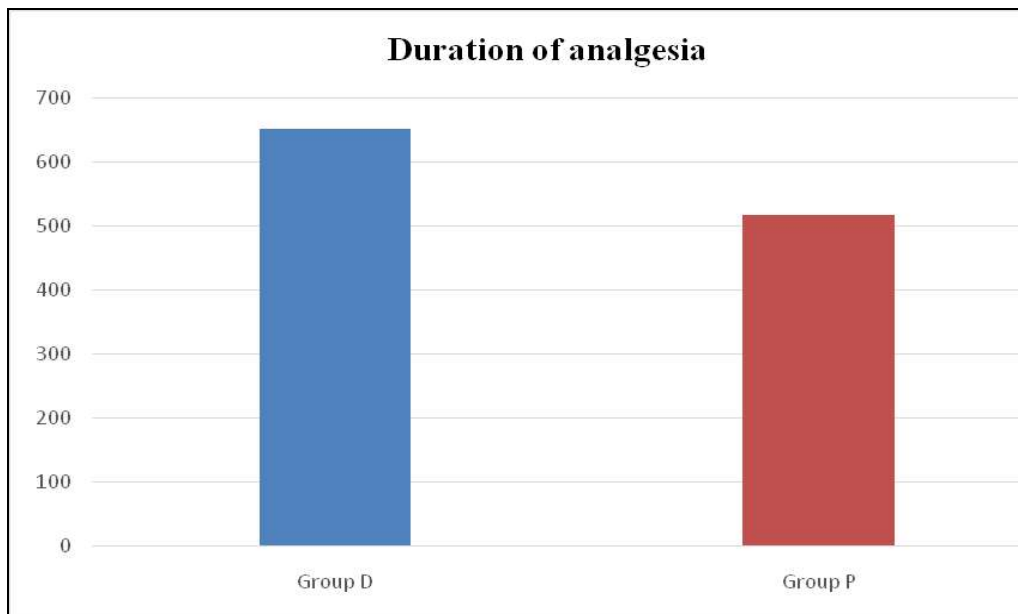
**Graph 3:** Duration of motor block

**Duration of Analgesia**

**Table 4:** Shows duration of analgesia lasted for 650.13±7.868minutes in Group D and 516.90±17.509minutes in Group P, with the difference between the two groups statistically significant *P* value< 0.001.

**Table 4:** Duration of analgesia

	Group D Mean ± SD	Group P Mean ± SD	P- Value
Duration of analgesia in minutes	650.13±7.87	516.90±17.50	<0.001



**Graph 4:** Duration of analgesia

**Haemodynamic Parameters**

Post block haemodynamic parameters like heart rate, systolic blood pressure, Diastolic blood pressure, mean arterial pressure, Peripheral oxygen saturation in percentage (SpO2) were normal in both the groups requiring no intervention and the differences between the two groups were statistically insignificant.

**Discussion**

This section is devoted for the discussion of the results of the present clinical study entitled “A clinical study of effects

of clonidine as adjuvant with ropivacaine in ultrasound guided axillary brachial plexus block” conducted to compare the effects of ropivacaine 0.75% 20ml + NaCl 0.9% (0.5ml) with ropivacaine 0.75% 20ml + clonidine 75µg (0.5ml) on the block characteristics, based on its objectives. After obtaining ethical committee clearance and written informed consent, 60 ASA status I and II patients, undergoing elective upper limb surgeries under ultrasound guided axillary brachial plexus block, were randomly divided into two groups Group D and Group P (30 each) to receive ropivacaine 0.75% 20ml + clonidine 75µg (0.5ml)

and ropivacaine 0.75% 20ml + NaCl 0.9% (0.5ml) respectively. All patients were administered ultrasound guided axillary brachial plexus block under aseptic precautions using the study drugs and the various parameters were studied.

In the present study ultrasound guided technique was chosen for administering axillary brachial plexus block as it offers many advantages over the conventional technique of nerve stimulation and paraesthesia like, providing a direct visualization of the anatomical structures, dynamic vision of the needle advancement and local anaesthetic spread around the nerve roots. It has also been shown to reduce the number of needle passes or redirections needed to perform the block, provide enhanced sensory and motor blocks, allow shorter procedure times with fewer vascular punctures, it may also reduce the incidence of major axillary block complications, as compared to the nerve stimulation technique [6, 7, 8].

The most commonly used local anaesthetics for peripheral nerve blocks are Lignocaine and Bupivacaine. The local anaesthetic Ropivacaine was chosen for the current study as it is a newer, long acting amide local anaesthetic with similar clinical properties, efficacy and duration of post-operative pain relief as that of the conventionally used bupivacaine, with the added advantage of being less lipophilic than bupivacaine, which accounts for its decreased central nervous system toxicity and cardiotoxicity, as proven by many authors like Usha badole *et al.*, Ajai Vikram Singh *et al.*, Veena Chatrath *et al.* [9, 10, 11].

A volume of 20ml of 0.5% of ropivacaine was used by Usha *et al.* where they have used ultrasound for giving the block. So from above studies it was concluded that the volume of 0.75% ropivacaine required for ultrasound guided axillary brachial plexus block was 20 ml. so the local anaesthetic volume of 20 ml of 0.75% Ropivacaine was chosen in the present study [9].

The advantage of Clonidine added as an adjuvant to Ropivacaine was rapid onset and prolonged duration of sensory and motor blockade. It also prolonged the duration of postoperative analgesia. Many authors have used different doses of Clonidine as an adjuvant to local anaesthetics such as studies done by researcher namely A. Duma *et al.*, A.H. El Saied *et al.*, Ajai Vikram Singh *et al.*, Jaiswal Rajmala *et al.*, Veena Chatrath *et al.* [12, 13].

In many of the above studies clonidine as an adjuvant has been used in the dose of 150µg and associated with sedation and a decrease in heart rate and blood pressure.

The use of ultrasound for local anaesthetic spread around the nerve roots has lead to early onset of sensory and motor blockade, decreasing the side effects so the dose of clonidine has been reduced to 75µg in our study. The administration of clonidine 75µg as an adjuvant have been used in our present study parameters.

### Sensory Block

#### Time of onset of sensory

The onset of sensory block in group D was in 5.80±0.847minutes, and in group P the onset of sensory block was in 7.93±0.907minutes. The difference between the two groups in terms of sensory block onset was statistically significant. *p* value<0.001.

These results were comparable with those obtained in the studies conducted by Kalyani Nilesh Patil *et al.* Usha Bafna

*et al.* [9, 14].

### Motor Block

#### Time of onset of motor block

The onset of motor block in group D was in 11.43±1.569minutes and in group P the onset of motor block was in 15.10±2.771minutes. The difference between the two groups in terms of motor block onset was statistically significant. *p* value <0.001.

The results are comparable with those obtained in the studies conducted by Kalyani Nilesh Patil *et al.* Usha Bafna *et al.* [9, 14].

#### Duration of motor block:

The duration of motor block lasted for 607.47±4.041minutes in group D and 479.03±10.118minutes in group P, with the difference between the two groups being statistically significant. *P* value <0.001.

The results are comparable with those obtained in the studies conducted by Ajai Vikram Singh *et al.* A.H. El Saied *et al.* Kalyani Nilesh Patil *et al.* Usha Bafna *et al.* [9, 11, 13, 14].

#### Duration of Analgesia

In our study duration of analgesia lasted for 650.13±7.868 minutes in Group D and 516.90±17.509minutes in group P, with the difference between the two groups statistically significant *P* value< 0.001.

The results are comparable with those obtained in the studies conducted by Ajai Vikram Singh *et al.* A.H. El Saied *et al.*, Kalyani Nilesh Patil *et al.* Usha Bafna *et al.* [9, 11, 13, 14].

**Hemodynamic parameters:** Post block hemodynamic parameters like pulse rate, systolic, diastolic and mean arterial pressures were within normal limits in both the groups requiring no intervention.

**Adverse effects:** None of the patients had any complications and the incidence of intraoperative bradycardia, hypotension, pneumothorax, intravascular injection, post block nausea, vomiting, convulsions, neuralgia were nil in either group.

Thus the present study shows that 20 ml of 0.75% Ropivacaine with clonidine 75 mcg prolonged the duration of motor, sensory block and duration of analgesia when compared with 20 ml of 0.75% Ropivacaine with NaCl 0.9% The onset of sensory, motor blocks was significantly faster with 0.75% Ropivacaine with clonidine 75 mcg group (Group D) when compared with 0.75% Ropivacaine with NaCl 0.9% group (Group P).

### Conclusion

From the present study it can be concluded that, the onset of sensory block and motor block, duration of sensory and motor block duration of analgesia was faster with clonidine as an additive group when compared to placebo group. Hence from the present study suggests that addition of clonidine 75µg as an adjuvant to 0.75% ropivacaine produces satisfactory sensory and motor blockade, with increased duration of analgesia when used for axillary brachial plexus block under ultrasound guidance without any adverse effects, with added advantage of cost effectiveness.

### References

1. Winnie AP *et al.* Factors affecting distribution of local

- anesthetic injected into the brachial plexus sheath  
*Anaesth. Analog.* 1979; 58:225-34.
2. Goldberg ME, Gregg C, Larijani GE *et al.* A comparison of three methods of axillary approach to brachial plexus blockade for upper extremity surgery. *Anesthesiology.* 1987; 66:814-6.
  3. McClure JH. Ropivacaine *Br J Anaesth.* 1996; 76:300-7.
  4. Bansal Teena. A study to evaluate the effect of addition of Clonidine to Ropivacaine for axillary plexus blockade, *Asian Journal of pharmaceutical and clinical research.* 2013; 6:3.
  5. Helmut Stähle *et al.* A historical perspective: development of clonidine. *Clinical anesthesiology.* 2000; 14(2):237-46.
  6. Nick Lo, Richard Brull, Anahi Perlas, Vincent WS, Chan Colin JL. Evolution of ultrasound guided axillary brachial plexus blockade: retrospective analysis of 662 blocks. *Can J Anesth.* 2008; 55(7):408-13.
  7. Denny NM, Harrop-Griffiths W. Location, location, location! Ultrasound imaging in regional anaesthesia. *Br J Anaesth.* 2005; 94:1-3.
  8. Marhofer P, Harrop-Griffiths W, Kettner SC, Kirchmair L. Fifteen years of ultrasound guidance in regional anaesthesia: Part 1. *Br J Anaesth.* 2010; 104:538-46.
  9. Usha badole, Akshay salunke. A comparative study of bupivacaine 0.5% and ropivacaine 0.5% in ultrasound guided axillary block. *Global journal for research analysis.* 2017; 6(10):42-4.
  10. Veena Chatrath, Radhe Sharan, Ranjana Kheterpal, Gagandeep Kaur, Jogesh Ahuja, Joginder Pal Attri *et al.* Comparative evaluation of 0.75% ropivacaine with clonidine and 0.5% bupivacaine with clonidine in infraclavicular brachial plexus block. *Anesthesia: Essays and Researches.* 2015; 9(2):189-94.
  11. Ajai Vikram Singh, Surinder Singh. Effects of clonidine as an adjuvant to ropivacaine for brachial plexus block via axillary approach. *IJIMS.* 2015; 5(2):45-50.
  12. Duma A, Urbanek B, Sitzwohl C *et al.* Clonidine as an adjuvant to local anesthetic axillary brachial plexus block: a randomized, controlled study. *Br J Anaesth.* 2005; 94(1):112-6.
  13. EI Saied AH, Steyn MP, Ansermino JM. Clonidine prolongs the effect of ropivacaine for axillary brachial plexus blockade. *Can J Anesthesia.* 2000; 47(10):962-7.
  14. Patil KN, Singh ND. Clonidine as an adjuvant to ropivacaine-induced supraclavicular brachial plexus block for upper limb surgeries. *J Anaesthesiol Clin Pharmacol.* 2015; 31:365-9.
  15. Jaiswal Rajmala, Bansal Teena, Mehta Sandeep, Ahlawat Geeta. A study to evaluate the effect of adding clonidine to ropivacaine for axillary plexus blockade. *Asian J Pharm Clin Res.* 2013; 6(3):165-8.