



International Journal of Medical Anesthesiology

E-ISSN: 2664-3774
P-ISSN: 2664-3766
www.anesthesiologypaper.com
IJMA 2020; 3(4): 36-40
Received: 25-08-2020
Accepted: 27-09-2020

Dr. Arjun Joshi
Graded Specialist, Department
of Anaesthesiology and Critical
Care GH Leh, Jammu and
Kashmir, India

Dr. JB Singh
Consultant Anaesthesiology,
and Commandant 153 GH
Leh, Jammu and Kashmir,
India

Dr. Anumeha Joshi
Assistant Professor,
Department of Anaesthesiology,
RML Hospital, New Delhi,
India

Corresponding Author:
Dr. Arjun Joshi
Graded Specialist, Department
of Anaesthesiology and Critical
Care GH Leh, Jammu and
Kashmir, India

Awake fibre optic intubation for difficult airway at high altitude of 12000 feet above mean sea level

Dr. Arjun Joshi, Dr JB Singh and Dr. Anumeha Joshi

DOI: <https://doi.org/10.33545/26643766.2020.v3.i4a.164>

Abstract

Awake fibre optic naso-tracheal intubation is a gold standard technique expedient in patients planned for maxillofacial surgeries with known difficult airways. The technique not only provides adequate depth of anaesthesia to secure the airway, it also facilitates maintenance of the spontaneous breathing by the patient. While managing a known difficult airway at high altitude maintaining the spontaneous breathing of the patient becomes all the more important due to the decrease in the partial pressure of the oxygen in the ambient air leading to early desaturation of the patient. In the present case infusion of Dexmedetomidine in combination with regional anaesthesia for upper airway blocks was used for smooth awake fibre optic naso-tracheal intubation. The present case is of an adult male patient who underwent oral maxillofacial surgery at a service hospital of the armed forces at a height of 12000 feet above mean sea level. 0.2 mg of Glycopyrrolate, 4 mg of Ondansetron were administered intravenously as pre-medication in the pre-op room 20 mins prior to wheeling the patient inside the operating room. In the operating room after attaching the standard ASA monitors the patient was administered with infusion of 0.3mcg/Kg/min of intra-venous Dexmedetomidine started 15 mins prior to the start of procedure. Oxygen was administered via nasal cannula at 4 L/min. An awake naso endotracheal intubation was performed after successful administration of regional block in the upper airways. The patient was successfully intubated and no complications were noted peri-operatively.

Keywords: Awake fibre, high altitude, dexmedetomidine

Introduction

Naso tracheal intubation provides unrestricted access of the oral cavity to the operating surgeon hence it is often preferred technique of securing the airway in maxillofacial surgery [1]. It has already been established in literature that awake fibre optic intubation is a gold standard technique in patients with an anticipated difficult airway, such as those with reduced mouth opening due to infection, temporomandibular joint problems, or mandibular fracture [2, 3]. It is expected that in patients with known difficult airway the anatomy may be digressed from normal [4]. An unprepared and unplanned approach to such an airway may lead to its complete airway loss leading to a situation of nothing less than an anaesthesiology disaster. In the high altitude where the partial pressure of oxygen in the ambient air is less, any delay in securing airway may lead to early desaturation and an increased morbidity and mortality in patients [5, 6].

Thus, close attention and detailed pre-op airway examination must be achieved to approach such airways in high altitudes. The awake fibre optic intubation requires adequate regional anaesthesia of the airway. Various publications in literature have reported that awake fibre optic intubation can be achieved with considerable haemodynamic stability under regional anaesthetic when combined with sedation [7, 8, 9]. However, in high altitude region careful titration of anaesthetic drugs becomes all the more important in providing the adequate anaesthesia plane due to early desaturation of the patient [4]. The ideal sedation technique enables patients to maintain spontaneous ventilation, to be cooperative, and to tolerate passage of a fiberscope to facilitate naso tracheal intubation. It is important for patients undergoing sedated—but awake—fibre optic intubation to have decreased anxiety, discomfort, and hemodynamic disturbances. While performing awake intubation, laryngospasm and coughing in response to intubation can be troublesome. Thus, effective regional airway anaesthesia is mandatory for the comfort of the awake patient and subsequent successful airway instrumentation. Moreover, successful regional anaesthesia of the airway reduces the requirement of higher doses of sedatives and analgesics [10, 11, 12]. Several undesirable elevations in the patient's sympathetic and parasympathetic tones leading to excessive salivation and gag and cough reflexes are known while performing Laryngo

bronchoscopy in an awake, unprepared patient which makes securing of the airway difficult [13, 14].

A knowledge of the of innervation of the airway and structures which need to be anaesthetized is essential while approaching for an awake intubation [15, 16].

The present case report is of awake fibre optic naso tracheal intubation of a 39-year-old male patient undergoing maxillofacial surgery performed at an altitude of 12000 feet above mean sea level under sedation using Dexmedetomidine in combination with regional airway blocks.

Relevant Anatomy

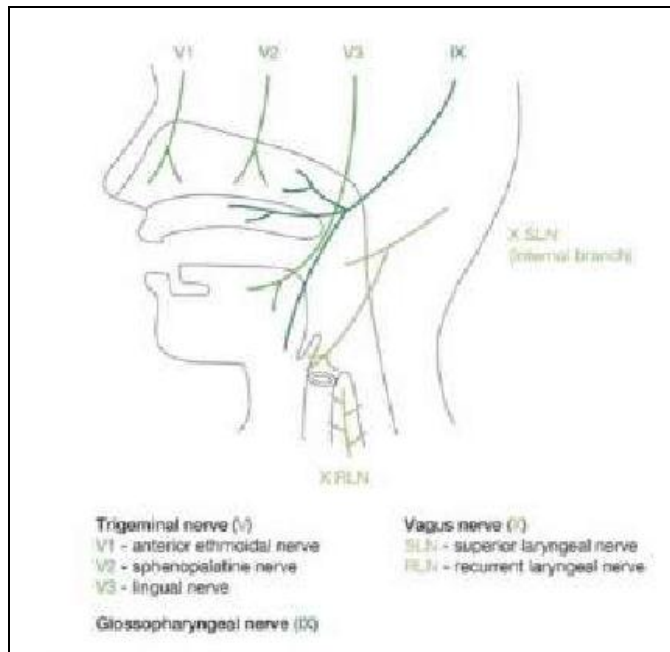


Fig 1: Nasal Cavity nerve supply [15, 16].

The nasal cavity and its turbinate is supplied by the Terminal branches of the ophthalmic and maxillary divisions (Fig. 1). The greater and lesser palatine nerves arising from the pterygopalatine ganglion innervate the nasal turbinate and most of the nasal septum. The anterior ethmoidal nerve arises from the olfactory nerve (CNI) and innervates the nares and the anterior third of the nasal septum) [15, 16].

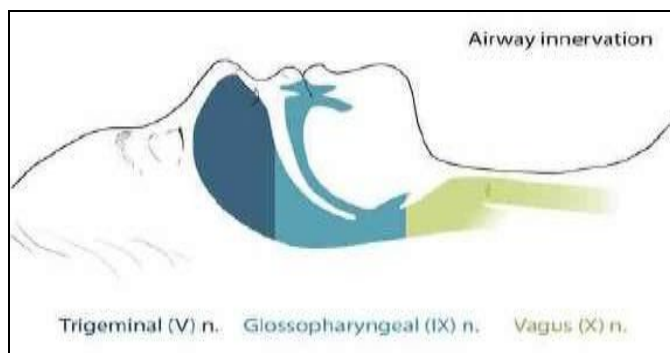


Fig 2: Relevant airway Nerve Supply [16, 17].

The glossopharyngeal nerve supplies the oropharynx and posterior third of the tongue. Fig.2 (The sensory innervation

of the anterior two thirds of the tongue is provide by the trigeminal nerve i.e. lingual branch of the mandibular division. it is not a part of the reflex arcs controlling gag or cough, its blockade is not essential for comfort during FOI.) [15, 16].

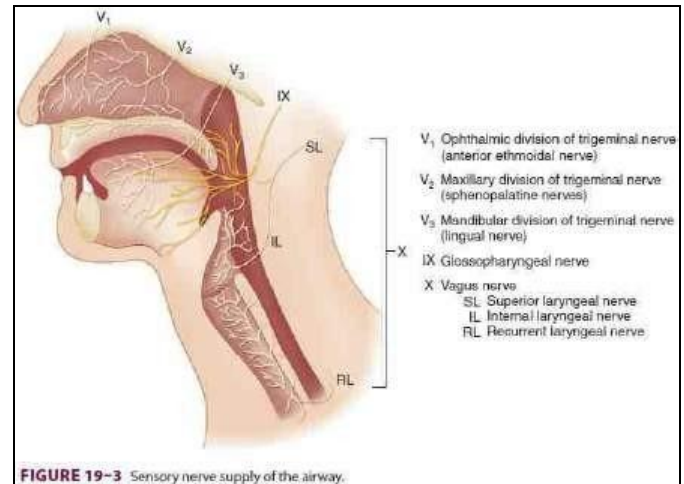


Fig 3: Branches of vagus nerve innervating epiglottis and distal airway structures [15, 16].

The following upper airway reflexes are required to be blocked before performing the awake fibre optic intubation [16, 17].

- a) **Gag reflex:** triggered by mechanical and chemical stimulation of areas innervated by the glossopharyngeal nerve, and the efferent motor arc is provided by the vagus nerve and its branches to the pharynx and larynx
- b) **Glottic closure reflex:** elicited by selective stimulation of the superior laryngeal nerve, and efferent arc is the recurrent laryngeal nerve. – exaggeration of this reflex is called laryngospasm.
- c) **Cough:** the cough receptors located in the larynx and trachea receive afferent and efferent fibres from the vagus nerve.

Case

The present case report is of a 39-year-old adult male serving army personnel without any co-morbidities posted in the high-altitude area at 12000 feet above the mean sea level, his clinical profile is summarized in Table 1. Patient was planned for maxillofacial surgery for fracture mandible under general anaesthesia. The restricted mouth opening and pre-op airway examination revealed of Mallampati class III which posed a threat to difficult mask ventilation and endotracheal intubation. Hence, as a safe anaesthesia strategy he was planned for awake fibre optic nasal endotracheal intubation under regional airway blocks and sedation. As a part of premedication and for preparation of the airway patient was administered i.v. 0.2 mg of Glycopyrrolate, 4mg of Ondansetron, in the pre-op room 30 minutes prior to the procedure. During this time patient was also nebulized with 2 ml of 2% Lignocaine in 5 ml of normal saline. In the Operating room after attaching all the standard ASA monitors infusion of Dexmedetomidine was started at the rate of 0.3 mcg/Kg/min while patient simultaneously received oxygen through nasal cannula @ 4lit/min.

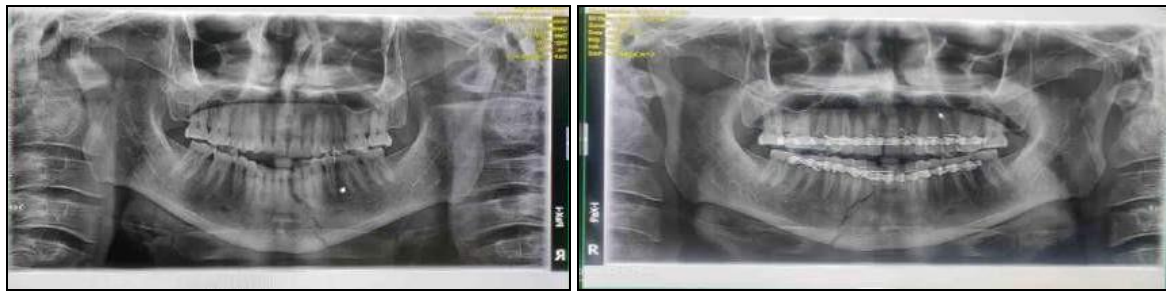


Fig 4: Reason for Awake fibre optic intubation (A,B) # mandible and Mallampati class III

Table 1.

Patient profile					
Age	Sex	Weight	Mallampati class	Sedation strategy	Indication
39	Male	70 Kgs	IV	Inj. Dexmedetomidine @ 0.3mcg/Kg/Min + Airway Blocks	Difficult airway anticipated in view of high Mallampati class and #mandible

Preparation of awake fibre optic nasal intubation

Patient was nebulized with 2ml of 2% lidocaine solution in 5 ml normal saline and i.v. Inj. Glycopyrrolate 0.2 mg, Inj. Ondansetron 4 mg were administered as premedication in the pre-op room. The nostrils of patient were also sprayed with 3 puffs of Xylometazoline nasal spray in both the nostrils. After a period of 20 minutes patient was wheeled inside the operating room. After attaching the standard ASA monitors infusion of Inj. Dexmedetomidine was started @ 0.3 mcg/Kg/min. 10 % Lidocaine was sprayed with in the posterior pharyngeal wall

to attenuate the gag reflex. After adequate level of sedation was achieved with anxiolysis/sedation, as defined by OAA/S level 3 or 4 [17] Superior Laryngeal Nerve was blocked by using 2 ml of 2% inj. Lidocaine on both sides while palpating the superior cornu of Hyoid bone as depicted in Fig5. Recurrent Laryngeal Nerve was blocked using a 24- gauge needle for instilling 4 ml of 2% Inj. Lidocaine through the cricothyroid membrane as depicted in Fig 6,7. After application of 2% lidocaine jelly into the patent nostril size 7.5 flexo-metallic endotracheal tube was introduced Fig 8.

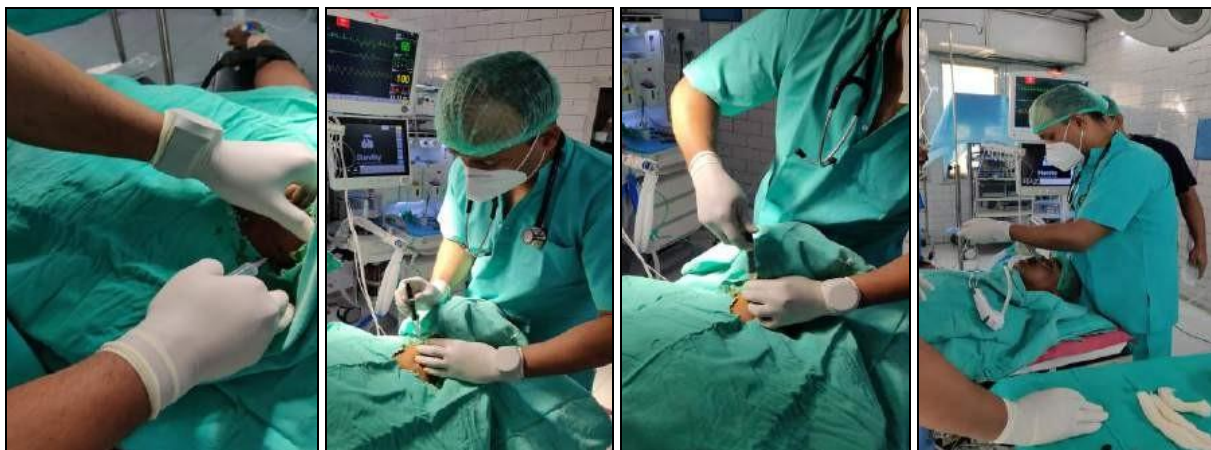

Fig 5, 6, 7, 8: (Administering regional anaesthesia airway block for Superior Laryngeal and Recurrent Laryngeal nerves)

Adult ambuscope was introduced through the endotracheal tube and was advanced till the visualization of epiglottis Fig.9. Using the SAYGO technique 5 ml of 2% of Inj. Lidocaine was sprayed in the subglottic structures as the ambuscope was advanced into the trachea Fig.10. Once the position of the ambuscope was confirmed by visualization of tracheal rings Fig.11 and carina Fig.12 the endotracheal tube was rail roaded over it. Reconfirmation of securing of the airway was done by the ETCO2 trace on the monitor and B/L air entry in all lung zones. Following this patient was administered with Inj. Propofol 80 mg i.v. along with Inj. Atracurium @0.5 mg/Kg and shifted to mechanical ventilation.

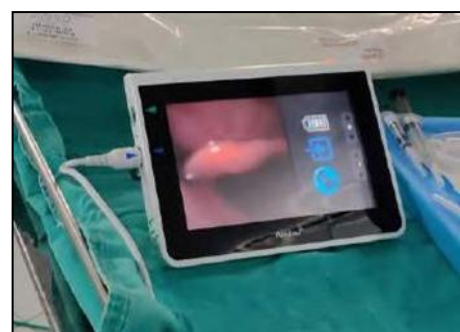

Fig 9: Visualization of epiglottis

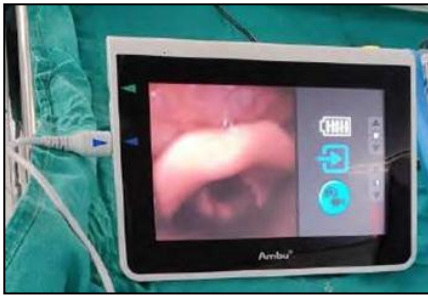

Fig 10: Visualization of vocal cords

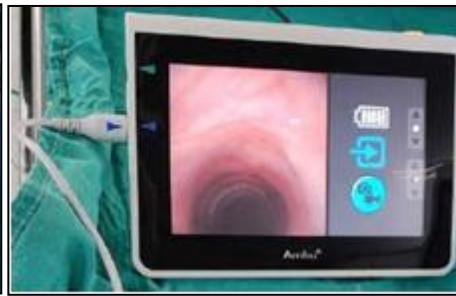

Fig 11: Visualization of Tracheal rings

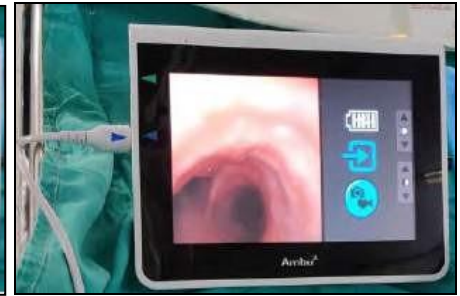

Fig 12: Visualization of carina

Anaesthesia was maintained using inhalational anaesthetic agents, and oxygen, in addition to an intravenous infusion of Dexmedetomidine. The surgeries proceeded uneventfully and post operatively patients was successfully extubated when fully awake. No complication was observed during the peri-operative period.

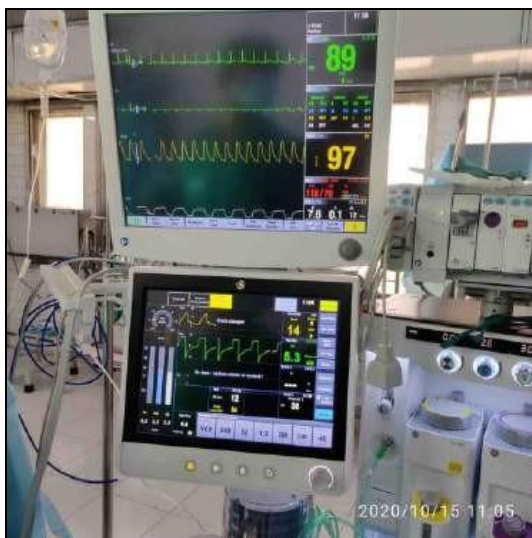

Fig 13: Intra operative monitoring of the patient

Discussion

In the plethora of complications that can occur at high altitude the unanticipated difficult airway is most severe. Detailed pre-operative airway examination and methodical approach is a key to effectively manage a difficult airway and prevent associated life-threatening complications [18, 22]. In a high altitude where the resources are in paucity and the environment is hostile it becomes all the more essential on the part of anaesthesiologist to pre-empt the airway complications and adapt to the technique which is safe and effective in taking the control of the difficult airway thus preventing the airway disasters [23]. 1–18% of patients have a difficult airway has already been established in literature [11]. Various clinical publications have already established awake fibre optic intubation as a gold standard technique in patients with an anticipated difficult airway [2, 3]. However, the success of the procedure largely depends on sedation and anxiolysis along with the effective regional airway blocks [10, 12]. In the present case scenario anticipation of difficult ventilation or intubation was made because of poor Mallampati classification, fracture of mandible and minimal mouth opening awake fibre optic naso tracheal intubation using regional airway blocks and intravenous administration of Dexmedetomidine infusion was selected as anaesthesia

technique. Unlike benzodiazepines and opioids like midazolam and fentanyl which cause respiratory depression Dexmedetomidine offers conscious sedation yet providing effective anxiolysis [30]. For these reasons, it was selected in the present case for providing conscious sedation to the patient while performing fibre optic intubation [11]. Previous studies, it was reported that midazolam (0.05–2.7 mg/kg), Propofol (1.0–2.7 mg/kg) as the primary sedative agent generally describe in combination with opioid such as fentanyl (1.0–3.0 µg/kg), Sufentanil (the target plasma concentration 0.3 ng/kg) or remifentanyl (0.25–0.75 µg/kg) [24, 25]. However, appropriate levels of sedation for safe awake intubation are very difficult to standardize because the required combination of anxiolysis and analgesia varies widely from case to case [26, 27].

References

1. Prasanna D, Bhat S. Nasotracheal Intubation: An Overview. *J Maxillofac Oral Surg* 2014;13:366-372.
2. Dhasmana S, Singh V, Pal US. Awake Blind Nasotracheal Intubation in Temporomandibular Joint Ankylosis Patients under Conscious Sedation Using Fentanyl and Midazolam. *J Maxillofac Oral Surg* 2010;9:377-381.
3. El-Boghdady K, Onwochei DN, Cuddihy J, Ahmad I. A prospective cohort study of awake fibre optic intubation practice at a tertiary centre. *Anaesthesia* 2017;72:694-703.
4. Benumof J. Management of the difficult adult airway. With special emphasis on awake tracheal intubation. *Anesthesiology* 1991;75:1087-110.
5. Hall J. Guyton and Hall textbook of medical physiology (Guyton Physiology) [Internet] Philadelphia, PA: Elsevier 2016.
6. Mellemaard K. The alveolar-arterial oxygen difference: its size and components in normal man. *Acta Physiol Scand* 1966;67:10–20.
7. Ovassapian A, Yelich SJ, Dykes MHM, Brunner EE. Blood pressure and heart rate changes during awake fibreoptic nasotracheal intubation. *Anesth Analg* 1983;62:951-4.
8. Sutherland AD, Williams RT. Cardiovascular responses and lidocaine absorption in fiberoptic- assisted awake intubation. *Anesth Analg* 1986;65:389-91.
9. Hawkyard SJ, Morrison A, Doyle LA, Croton RS, Wake PN. Attenuating the hypertensive response to laryngoscopy and endotracheal intubation using awake fibreoptic intubation. *Acta Anaesthesiol Scand* 1992;36:1-4.
10. Xue FS, Liu HP, He N, Xu YC, Yang QY, Liao X, *et al.* Spray-as-you-go airway topical anesthesia in

- patients with a difficult airway: a randomized, double-blind comparison of 2% and 4% lidocaine. *Anesth Analg* 2009;108:536–543.
11. Shen SL, Xie YH, Wang WY, Hu SF, Zhang YL. Comparison of dexmedetomidine and sufentanil for conscious sedation in patients undergoing awake fiberoptic nasotracheal intubation: a prospective, randomised and controlled clinical trial. *Clin Respir J* 2014;8:100-107.
 12. Johnston KD, Rai MR. Conscious sedation for awake fiberoptic intubation: a review of the literature. *Can J Anaesth* 2013;60:584-599.
 13. Telford RJ, Liban JB. Awake fiberoptic intubation. *Br J Hosp Med* 1991;46:182-4
 14. Ovassapian A, Yelich SJ, Dykes MHM, Brunner EE. Blood pressure and heart rate changes during awake fiberoptic nasotracheal intubation. *Anesth Analg* 1983;62:951-4
 15. Raj PP, Foresmer J, Watson TD, Morris RE, Jenkins MT. Techniques for fiberoptic laryngoscopy in anesthesia. *Ancsth Analg* 1974;53:708-13.
 16. Reed AP, Han DG. Preparation of the patient for awake fiberoptic intubation. *Anesthesiology Clinics of North America* 1991;9:69-81.
 17. Sedation with regional anesthesia: Inter-rater agreement on a modified Wilson sedation scale. *Anesth Analg* 2002;94:723-8.
 18. Mallampati SR, Gatt SP, Gugino LD, Desai SP, Waraksa B, Freiburger D, *et al.* A clinical sign to predict difficult tracheal intubation: A prospective study. *Can Anaesth Soc J* 1985;32:429-34.
 19. Janssens M, Hartstein G. Management of difficult intubation. *Eur J Anaesthesiol* 2001;18:3-12
 20. Wilson ME, Spiegelhalter D, Robertson JA, Lesser P. Predicting difficult intubation. *Br J Anaesth* 1988;61:211-6
 21. Randell T. Prediction of difficult intubation. *Acta Anaesthesiol Scand* 1996;40:1016-23.
 22. Yentis SM. Predicting difficult intubation: Worthwhile exercise or pointless ritual? *Anaesthesia* 2002;57:105-9.
 23. Cohen JE, Small C, *et al.* Hypsographic demography: the distribution of human population by altitude *Proc Natl Acad Sci USA* 1998;95:14009–14.
 24. Bergese SD, Candiotti KA, Bokesch PM, Zura A, Wisemandle W, Bekker AY, *et al.* A Phase IIIb, randomized, double-blind, placebo-controlled, multicenter study evaluating the safety and efficacy of dexmedetomidine for sedation during awake fiberoptic intubation. *Am J Ther* 2010;17:586-95.
 25. Kumar P, Kaur T, Atwal GK, Bhupal JS, Basra AK. Comparison of Intubating Conditions using Fentanyl plus Propofol Versus Fentanyl plus Midazolam during Fiberoptic Laryngoscopy. *J Clin Diagn Res* 2017;11:21-24.
 26. Barends CR, Absalom A, van Minnen B, Vissink A, Visser A. Dexmedetomidine versus Midazolam in Procedural Sedation. A Systematic Review of Efficacy and Safety. *PLoS One* 2017;12:e0169525.
 27. Dhasmana S, Singh V, Pal US. Awake blind nasotracheal intubation in tm joint ankylosis patients under conscious sedation using fentanyl and midazolam. *J Maxillofac Oral Surg* 2010;9:377-381.