



International Journal of Medical Anesthesiology

E-ISSN: 2664-3774
P-ISSN: 2664-3766
www.anesthesiologypaper.com
IJMA 2021; 4(1): 152-156
Received: xx-11-2020
Accepted: xx-12-2020

Dr. Gunjan Singh
Assistant Professor,
Department of Anesthesiology,
Critical Care Command
Hospital, Chand Mandir,
Haryana, India

Dr. Arjun Joshi
MNAMS Specialist
Anaesthesia 153 General
Hospital, Leh, Ladakh,
Jammu and Kashmir, India

Dr. BC Nambiar
Deputy Commandant, AHRR,
New Delhi, India

Dr. Siddharth Chaki
Specialist, Anesthesiology,
Department of Anesthesiology,
Base Hospital Delhi Cantt,
India

Corresponding Author:
Dr. Arjun Joshi
MNAMS Specialist
Anaesthesia 153 General
Hospital, Leh, Ladakh,
Jammu and Kashmir, India

Will the use of gastric tube guide facilitate the insertion of orogastric tube for gastric decompression in ASA I and II patients without any obvious/difficult airway posted for laparoscopic surgeries?

Dr. Gunjan Singh, Dr. Arjun Joshi, Dr. BC Nambiar and Dr. Siddharth Chaki

DOI: <https://doi.org/10.33545/26643766.2021.v4.i1c.210>

Abstract

Gastric decompression and reduction in gastric volume is routinely practiced in clinical anaesthesiology and intensive care medicine and the use of oro-gastric tube to achieve decompression is widely known technique. Nonetheless, this may be challenging and is concomitant with severe complications including but not restricted to failure to pass the oro-gastric tube beyond crico-pharynx, coiling in oral cavity, upper airway trauma, laryngeal injuries, esophageal perforation, bleeding and post procedure throat discomfort. In clinical anaesthesiology and in intensive care medicine the orogastric tube insertion is mostly done after general anaesthesia induction. The procedure becomes all the more challenging due to the attenuation of airway reflexes and loss of consciousness rendered by general anaesthesia. The present study was conducted in the department of Anaesthesiology and Critical Care at a tertiary care center of Armed Forces to evaluate if the usage of the new gastric tube guide would ease and accelerate the placement of oro-gastric tube while simultaneously reducing the complications arising out of the procedure.

Material and Methods: The present study is a first randomized controlled study done on live patients. The study was conducted on the patients undergoing elective laparoscopic surgery who required gastric decompression as the part of the procedure at the Department of Anaesthesiology and Critical Care, of a tertiary care hospital of armed forces.

Study Design: Prospective randomized controlled study.

Study Location: Tertiary care hospital of armed forces.

Study Duration: Aug 2019 to Aug 2020.

Sample Size: 100 patients.

Subject and Selection Method: After taking ethical approval of the institute and informed consent from patients hundred patients aged between 18 to 65 years of either sex, accepted in Mallampati classification I and II and without any obvious airway abnormalities who were scheduled for elective laparoscopic surgery and required gastric decompression as a part of procedure were included in the study. The participants were then randomly assigned to one of the two groups of 50 patients each to undergo oro-gastric tube insertion using gastric tube guide and those without it.

Results: Passage of the oro-gastric tube was successful during the first pass in 38 patients (76%) in the Group A i.e. gastric tube guide group against 15 (30%) patients in the group B i.e. non-gastric guide group. (4%) patients in Group A required three or more attempts against 11 (22%) patients Group B. The mean time taken for the passage of the oro-gastric tube successfully in the Group A was 21.90 ± 16.33 against 80.14 ± 49.78 secs in the group B ($p < 0.001$). The results obtained support the observation that passage of the oro-gastric tube with the gastric tube guide is associated with a higher success rate in first attempt than without it. Moreover, it also shows that the time duration for securing oro-gastric tube is significantly low using gastric tube guide.

Conclusion: The present study it was found that use of gastric tube guide avoids the shambolic and arduous measures of failed nasogastric tube insertions while significantly reducing the duration of procedure.

Keywords: Gastric tube guide, orogastric tube

1. Introduction

Gastric decompression and reduction in gastric volume is routinely practiced in clinical anaesthesiology and intensive care medicine and the use of oro-gastric tube to achieve decompression is widely known technique. Nonetheless, this may be challenging and is

concomitant with severe complications including but not restricted to failure to pass the oro-gastric tube beyond crico-pharynx, coiling in oral cavity, upper airway trauma, laryngeal injuries, esophageal perforation, bleeding and post procedure throat discomfort^[1, 2] with high failure rates of nearly up to 50% for the first attempt has been reported in literature^[3, 4, 5]. Since in the clinical anaesthesiology and in intensive care medicine the orogastric tube insertion is mostly done after induction of anaesthesia this procedure becomes even more challenging due to attenuation of airway reflexes and loss of consciousness of the patient making them unable to swallow and follow any directions for placement of oro gastric tubes^[6]. Further, as the gastric tube loses stiffness after warming to body temperature increased number of attempts of tube placement will often result in increased successive failures^[7]. Several studies suggest that the arytenoid cartilages and piriform sinuses are two usual sites of resistance at the laryngeal level^[8]. Different techniques to aid gastric tube insertion, including anterior displacement of the larynx, lateral neck pressure, use of endotracheal tubes split longitudinally as an introducer, and immersion of the gastric tube in ice water to harden it before use have been proposed in clinical publications^[9, 10]. The gastric tube guide is designed on the concept of slit endotracheal tubes so as to facilitate the insertion of oro-gastric tubes. It is made of polyvinyl chloride and has a pre-curved shape to follow the anatomical structures of the pharynx. Presence of graduation marks along its curvature help in adjusting the placement of gastric tube guide. The proximal end of gastric tube guide has an insertion funnel which facilitates the gliding of the oro-gastric tubes. Moreover, its design includes an atraumatic tip which decreases the risk of mucosal bleeding during its placement. The slit shaft design of the gastric tube guide facilitates in the removal of the device without removing the oro-gastric tube. The present study was conducted in the department of Anesthesiology and Critical Care at a tertiary care center of the armed forces to evaluate if the usage of the gastric tube guide would ease and accelerate the placement of oro-gastric tube while simultaneously reducing the complications arising out of the procedure.

2. Material and Methods

A randomized controlled study was conducted on the patients undergoing elective laparoscopic surgery who required gastric decompression as the part of the procedure at the Department of Anaesthesiology and Critical Care, of a tertiary care hospital of armed forces from August 2019 to August 2020. A total of 100 patients of either sex were included in the study.

Study design: Prospective randomized controlled study.

Study location: Tertiary care hospital of armed forces

Study duration: Aug 2019 to Aug 2020

Sample size: 100 patients

Subject and selection method: After taking informed consent hundred patients aged between 18 to 65 years of both genders accepted in Mallampati classification I and II and without any obvious difficult airway abnormalities

scheduled for elective laparoscopic surgery who required gastric decompression as the part of the procedure were included in the study. The participants were then assigned to one of the two groups of 50 patients each in a manner to undergo oro-gastric tube insertion using gastric tube guide and those without it.

A. Inclusion criteria

1. Patients willing to participate in the study
2. Mallampati class I and II and without any anticipated airway abnormality
3. Patients undergoing elective laparoscopic surgeries who required general anaesthesia, endotracheal intubation, and orogastric tube insertion as part of the procedure.
4. Patients between ages 18 to 65 years of both genders

B. Exclusion criteria

1. Unwilling to participate in the study
2. Patients with coagulopathies or contraindication for oro gastric tube insertion
3. Mallampati class III and IV and those with any anticipated airway abnormalities
4. Age ≤ 18 years or ≥ 65 years

3. Procedure Methodology

For commencement of the study following standard ASA monitoring endotracheal intubation was achieved following standard anaesthesia technique using Inj. Fentanyl 2 mcg/Kg, Inj. Propofol 2mg/Kg and Inj. Vecuronium 0.1 mg/Kg. Participants were then randomly assigned to one of the two groups of 50 patients. Group A i.e. (Gastric tube guide group) and Group B i.e. (Non-Gastric Tube Guide group) to undergo orogastric tube placement through gastric tube guide and those without it. Post securing the airway the head of the patient in both the groups was placed in a neutral position. In group A after application of 2% lignocaine jelly on the outer as well as inner surface gastric tube guide a 14-French oro gastric tube was blindly inserted through the lumen of the pre-lubricated gastric tube guide. Following confirmation of placement of the orogastric tube through auscultation technique the gastric tube guide was safely withdrawn while holding the cranial end of oro gastric tube. The position of the orogastric tube was reconfirmed after removal of the gastric tube guide using the auscultation technique following which it was secured. In group A anaesthesiologists performed no further maneuvers while inserting the gastric tube guide or the orogastric tube. In group B, the oro-gastric tube was tried to be inserted blindly while the head in remained in the neutral position. If there were two unsuccessful attempts in the intended position, the anaesthesiologist was allowed to perform additional maneuvers *viz.* use of Magill forceps, anterior displacement of the larynx, lateral neck pressure, use of endotracheal tubes split longitudinally as an introducer, and immersion of the gastric tube in ice water to harden it to aid the successful passage of the orogastric tube.

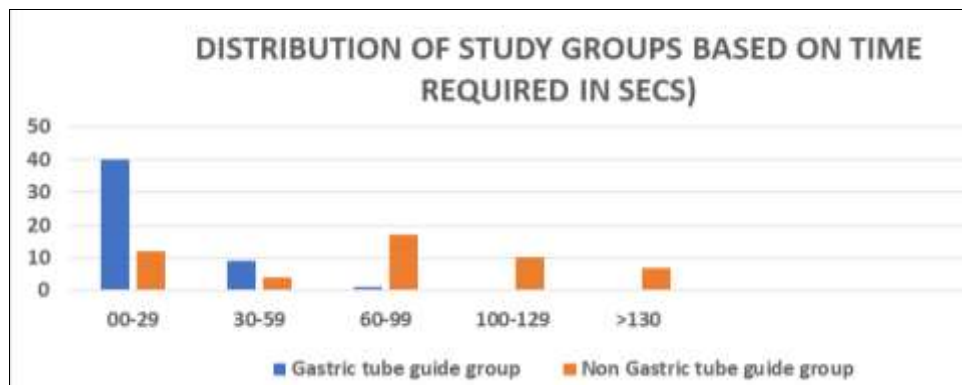
While inserting the orogastric tube in both the groups the following parameters were noted

- a. The time for the procedure
- b. Number of attempts involved, complications/additional efforts

4. Statistical Analysis

Table 1: Distribution of study groups based on Mallampati class, and anthropometric parameters (age and gender), time required, No. of attempts.

Distribution of study groups based on Mallampati classification				
Mallampati Class	Gastric Tube Guide group A	Non-Gastric Tube Guide Group B	Unpaired t Test	P value
Class 1	23	23	0.31	0.2098
Class 2	27	27		
Mean ± SD)	1.46 ± 0.49	1.54 ± 0.4983		
Distribution of study groups based on age (n=100)				
Age (in years)	Gastric Tube Guide group an (%)	Non- Gastric Tube Guide group B n (%)	Total n %	P value
18-30	15	13	28 (28.0)	0.88616
31-45	16	19	35 (35.0)	
45-60	14	12	26 (26.0)	
>60	5	6	11 (11.0)	
Total	50 (100)	50 (100)	100 (100.0)	
Distribution of study groups based on gender (n=100)				
Gender	Gastric Tube Guide group An (%)	Non Gastric Tube Guide group n(%)	Total n %	P value
Male	24 (24.0)	26 (26.0)	50.0 (100.0)	0.689157
Female	26(26.0)	24 (24.0)	50 (100.0)	
Total	50	50	100 (100.0)	
Distribution of study groups based on time required in seconds (n=100)				
Gastric Tube Guide MEAN ± SD/SEM		Non-Gastric Tube Guide group MEAN ± SD/SEM		P value
Time (in secs)	21.90 ± 16.33 /2.31	80.14 ± 49.78/7.04	Difference in mean (95 % CI)	<0.0001
			-75.92 TO -43.52	
Distribution of study groups based on number of attempts				
Gastric Tube Guide MEAN ± SD/SEM		Non-Gastric Tube Guide group MEAN ± SD/SEM		P value
Number of attempts	1.30 ± 0.54 /0.08	1.94 ± 0.77 /0.11	Difference in mean (95 % CI)	<0.0001
			--0.90 to -0.38	



The values are statistically highly significant

Fig 1: Distribution of study groups based on time required in secs

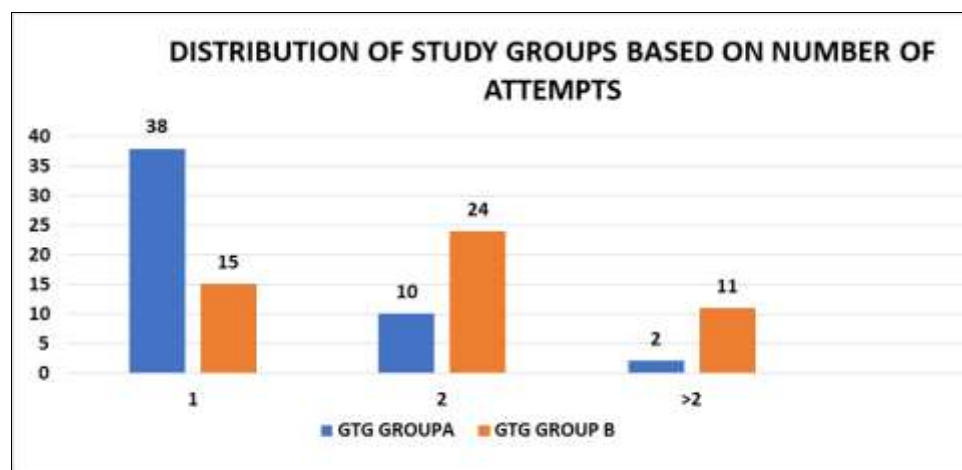


Fig 2: Distribution of study groups based on number of attempts

5. Result

The number of attempts required for successful insertion was recorded for each patient the results are summarized in table 1. Fifty patients were allocated to the gastric tube guide group i.e. group A, and 50 were allocated to the non-gastric tube guide group i.e. group B. Time duration required for successful passage of gastric tube in Group A was noted at 21.90 ± 16.33 secs against 80.14 ± 49.78 secs in Group B with p value of <0.0001 . Similarly, the number of attempts to pass the oro gastric tube in Group A was noted at 1.30 ± 0.54 against 1.94 ± 0.77 in Group B with a p value of <0.001 which was statistically significant as summarized in Table 1 and Fig 1, 2. The result obtained in the present study indicate that passage of the oro-gastric tube with the gastric tube guide is associated with a higher success rate in the first attempt than without it. Moreover, the use of gastric tube guide avoids some of the shambolic and arduous measures of failed oro-gastric tube insertions.

6. Discussion

Gastric decompression and gastric volume reduction is commonly practiced yet cumbersome procedure in clinical anaesthesiology and in intensive care wards. The difficulties associated with the procedure not only make it a time-consuming task, they are also associated with complications including but not restricted to failure to pass the oro gastric tube beyond crico-pharynx, coiling in oral cavity, upper airway trauma, laryngeal injuries, esophageal perforation, bleeding and post procedure throat discomfort^[1,2] with high failure rates of nearly up to 50% for the first attempt has been reported in literature^[3,4,5]. Since in the operating room and Intensive care ward setting the orogastric tube insertion is mostly done after induction of anaesthesia this procedure becomes even more challenging due to attenuation of airway reflexes and loss of consciousness of the patient making him unable to swallow and follow any directions for placement of oro gastric tubes^[6]. Further, as the gastric tube loses stiffness after warming to body temperature any further attempts of tube placement will often result in successive failures^[7]. Several studies suggest that the maximal resistance to the tip of orogastric tube is at the level of arytenoid cartilages and piriform sinuses which not only restrict its passage into esophagus but also often result in its coiling in the upper airway^[8]. The ease of placement of oro gastric tube is increased when used along with the gastric tube guide since it anatomically restricts the oro gastric tube from coming in contact with these structures and this is hypothesized to be the reason for the faster placement of the orogastric tube.

Although various other methods have been published in literature for placement of the orogastric tubes there associated complications cannot be overlooked. Kwon OS, *et al.* showed an increased risk for mucosal bleeding during this gastric tube placement using slit endotracheal tubes for placement of gastric tubes due to its inherent hard, and relatively sharper ends^[9]. Various other studies advocated the use of laryngoscope along with the Magill's forceps for the placement of orogastric tube but this method may also result in injuries to the tongue and teeth not to mention the increased exposure of the anaesthesiologists with the patient's airway^[11]. Moreover, blood in the oropharynx can be the result of traumatic insertion of the gastric tube, particularly if the gastric tube was inserted without actively creating sufficient retropharyngeal space by means of a chin

lift manoeuvre or with a laryngoscope^[11]. Another problem noted during the insertion of oro-gastric tube under direct or indirect laryngoscopy is the space in the oral cavity: The oral tube and the blade often do not allow placing the gastric tube although the esophageal entrance is under direct or indirect vision^[12]. Various other techniques to aid gastric tube insertion, including anterior displacement of the larynx, lateral neck pressure, and immersion of the gastric tube in ice water to harden it before use have been proposed in clinical publications but they are associated with their own share of complications and short falls^[9,10].

A need was felt to devise a method which not only increases the successful placement of oro gastric tube in first or minimal attempts, it also decreases the associated complication and frustrations arising out of the failure of the procedure.

The gastric tube guide is based and designed on the concept of slit endotracheal tubes so as to facilitate the insertion of oro-gastric tubes. It is made of polyvinyl chloride and has a pre-curved shape to follow the anatomical structures of the pharynx. The presence of graduation marks help in adjusting its placement. The length of gastric tube guide is 33 cm, with an outer diameter of 10.3 mm and an inner diameter of 7.5 mm, allowing the placement of gastric tubes up to 6.0 mm (18 Fr). The proximal end of GTG has an insertion funnel which facilitates the gliding of the oro gastric tubes. Moreover, the design of the gastric tube guide includes an atraumatic tip which decreases the risk of mucosal bleeding during its placement. The slit shaft design of the device facilitates in its removal without removing or displacing the orogastric tube. The present study was conducted in the department of Anaesthesiology and Critical Care at a tertiary care center of the armed forces to evaluate if the usage of the new gastric tube guide would ease and accelerate the placement of oro-gastric tube while simultaneously reducing the complications arising out of the procedure.

In the present study, equal distribution was noted in both the groups based on anthropometric parameters *viz.* gender (p value 0.68), Mallampati class (p value 0.20) and age (p value 0.88). It was also noted that significant difference was present in the time required for successful placement of oro-gastric tube with mean value of 21.90 ± 16.33 secs noted in gastric tube guide group A against 80.14 ± 49.78 secs noted in non-gastric tube guide group B (p value <0.001) with difference of means of 75.92 TO - 43.52. Further it was also seen that the mean of number of successful attempts for securing the oro gastric tube in group A was 1.30 ± 0.54 against 1.94 ± 0.77 in non-gastric tube guide group with difference of mean in both the groups of -0.90 to -0.38 (p value <0.0001) which was statistically significant.

7. Conclusion

The present study shows that gastric tube guide significantly reduces time required for successful placement of orogastric tube in Mallampati class I and II patients and in those patients without any obvious/difficult airway. There is also a higher success rate in the first attempt for the placement of orogastric tube using the gastric tube guide in such patients. We strongly recommend the usage of gastric tube guide as a routine procedure for placement of oro-gastric tube in all intubated and mechanically ventilated patients where there is no contraindication of the usage of orogastric tube or in those patients who do not require post-operative naso gastric

tubes. No study has been done on live subjects using this device till date.

8. References

1. Burad J, Deoskar S, Bhakta P *et al.* Avoidance of Laryngeal Injuries during Gastric Intubation. Sultan Qaboos Univ Med J. 2014;14:e405-8.
2. Turabi AA, Urton RJ, Anton TM *et al.* Esophageal perforation and pneumothorax after routine intraoperative orogastric tube placement. Case Rep 2014;2:122-4. doi: 10.1002/ccr3.77
3. Bong CL, Macachor JD, Hwang NC. Insertion of the nasogastric tube made easy. Anesthesiology 2004;101:266.
4. Ching YH, Socias SM, Ciesla DJ *et al.* The difficult intraoperative nasogastric tube intubation: a review of the literature and a novel approach. SAGE Open Med 2014;2:1-7.
5. Appukutty J, Shroff PP. Nasogastric tube insertion using different techniques in anesthetized patients: a prospective, randomized study. Anesth Analg 2009;109:832-5. doi:
6. Boyes RJ, Kruse JA. Nasogastric and naso enteric intubation. Crit Care Clin 1992; 8:865-78.
7. Ozer S, Benumof JL. Oro- and nasogastric tube passage in intubated patients: fiber optic description of where they go at the laryngeal level and how to make them enter the esophagus. Anesthesiology. 1999; 91:137-43. doi: 10.1097/00000542-199907000-00022. [
8. Burad J, Deoskar S, Bhakta P, *et al.* Avoidance of Laryngeal Injuries during Gastric Intubation. Sultan Qaboos Univ Med J 2014;14:e405-8.
9. Kwon OS, Cho GC, Jo CH, Cho YS. Endotracheal tube-assisted orogastric tube insertion in intubated patients in an ED. Am J Emerg Med 2015;33:177-80. doi: 10.1016/j.ajem.2014.11.004. [
10. Moharari RS, Fallah AH, Khajavi MR *et al.* The GlideScope facilitates nasogastric tube insertion: A randomized clinical trial. Anesth Analg 2010;110:115-118.
11. Boedeker BH, Bernhagen MA, Miller DJ *et al.* Comparison of the Magill forceps and the Boedeker (curved) intubation forceps for removal of a foreign body in a manikin. J Clin Anesth 2012;24:25.
12. Mahajan R, Gupta R. Another method to assist nasogastric tube insertion. Can J Anesth 2005;52:652-653.
13. Metheny NA, Meert KL, Clouse RE. Complications related to feeding tube placement. Curr Opin Gastroenterol 2007;23:178-82.