



# International Journal of Medical Anesthesiology

E-ISSN: 2664-3774  
P-ISSN: 2664-3766  
[www.anesthesiologypaper.com](http://www.anesthesiologypaper.com)  
IJMA 2021; 4(2): 121-123  
Received: 21-02-2021  
Accepted: 26-03-2021

**Dr. Sumedha Mehta**  
Assistant Professor, Smt.  
Kashibai Navale Medical  
College and General Hospital,  
Pune, Maharashtra, India

**Despande P Jyoti**  
Professor, Smt. Kashibai  
Navale Medical College and  
General Hospital, Pune,  
Maharashtra, India

**Jain R Lisha**  
Post Graduate Resident, Smt.  
Kashibai Navale Medical  
College and General Hospital,  
Pune, Maharashtra, India

**Corresponding Author:**  
**Dr. Sumedha Mehta**  
Assistant Professor, Smt.  
Kashibai Navale Medical  
College and General Hospital,  
Pune, Maharashtra, India

## Successful fiberoptic intubation of difficult airway in an acid burn patient using 2% lignocaine spray as you go method and conscious sedation with dexmedetomidine: A case report

**Mehta Sumedha, Despande P Jyoti, Jain R Lisha and Dr. Sumedha Mehta**

**DOI:** <https://doi.org/10.33545/26643766.2021.v4.i2b.243>

### Abstract

Management of difficult airways is widely recognized as one of the important tasks of an anesthesiologist. One of the commonly encountered difficult airway is of post- burns contractures leading to restriction of mouth opening and neck movements. Proper planning and skillful execution to secure airway is of utmost importance as failure may lead to cannot ventilate and cannot intubate situation. We present a case of successful fiberoptic oral intubation in 88yr old blind, hypertensive female patient with post acid burn contractures with difficult airway and narrow nasal passages using spray as you go technique and balanced conscious sedation.

**Keywords:** Difficult airway, fiberoptic, acid-burns, spray as you go, dexmedetomidine

### Introduction

Acid burn is becoming a major social concern in developing country like India. The effect of acid burn on a person involves a long struggle from surviving an acute phase to chronic recovery phase with mental and emotional challenges. Patients with face/neck burns seem to be at a higher risk of having difficult intubation estimated to be from 5% to 11% [1]. In chronic burn patients, there are multiple challenges from securing intravenous access to managing a difficult airway. The underlying dense fibrous hypertrophic sheets of scar may displace the epiglottis and vocal cords anteriorly and pull towards the scar, circumoral and mento-sternal contractures may limit the mouth opening, nasal orifices may be narrowed with inability to advance nasal airways [2]. Induction of general anesthesia becomes unsafe because both mask ventilation and intubation may be difficult to perform, in such cases the awake fiberoptic intubation provides the safest option. Awake fiberoptic intubation is considered as the gold standard in airway management of patients with anticipated difficult airway [3]. In chronic burns identification of airway problems is easy but its management is a true challenge as scope of conventional measures like direct laryngoscopy and LMA insertion becomes limited due to restricted mouth opening. Lidocaine 2% administered topically by spray-as-you-go technique can provide clinically acceptable intubating conditions for awake oral fiberoptic intubation in patients with a difficult airway [4]. We present a case of successful awake oral fiberoptic intubation with 2% lignocaine spray as you go technique and conscious sedation with dexmedetomidine in a patient with post-burn limited mouth opening and restricted neck extension with bilateral nasal narrowing.

### Case report

An 88 years old, hypertensive female patient weighing 40kg, with history of chronic burns was diagnosed with Marjolin's ulcer of left forearm and was posted for left elbow disarticulation with axillary lymph node dissection. The patient had a history of acid attack 40 years back and had required ventilator for maintenance of airway. The patient had suffered from severe acid burns over her face, neck, chest, both upper limbs, right leg with complete loss of vision in both eyes. There were h/o multiple admissions to government hospital for various reconstructive plastic surgery of nose and face over a period of 4 years following the acid attack.

On Airway examination, mouth opening was restricted to 1 and 1/2 fingers due to multiple burn contracture over the face and neck. There were protruding front teeth, deformed lower lips and multiple missing teeth indicating difficult airway. She had deformed bilateral nasal passage narrowing with a history of nasal reconstructive surgery. It was difficult to assess sternomental and thyromental distances due to neck contracture. Neck movements were limited due to neck contractures. Anatomical landmarks for airway blocks were difficult to appreciate because of scars over neck. Chest X-ray and X-ray neck were normal, no tracheal deviation or compression was seen. After thorough clinical examination, investigation and optimization, patient was posted for surgery. Our plan of anesthesia was General anesthesia as per requirement of surgery. We have planned for awake oral fiberoptic intubation. As the patient was old, blind, and anxious we explained the procedure of awake intubation and allayed all her anxiety. Preoperatively, after taking informed written consent and confirming NBM status, a wide bore intravenous access was secured, and Ringer lactate was started. The patient was nebulized with lignocaine 4% solution half hour prior to the surgery. In operating room, difficult airway trolley along with fiberoptic bronchoscope and tracheostomy set was kept ready. After attaching standard monitors like ECG, pulse oximeter and NIBP, patient was given Oxygen by nasal prongs @ 3 L/min. Premedication in the form of Inj. Glycopyrrolate 0.2mg IV, Inj. Hydrocortisone 100mg IV, Inj. Ondansetron 4 mg IV, Inj. Midazolam 0.5 mg IV and Inj. Dexmedetomidine 30 mcg IV bolus over 10 mins were given for providing adequate conscious sedation to facilitate awake fiberoptic intubation. Adult fiberoptic bronchoscope was loaded with cuffed ETT No-7. Oropharynx cavity was sprayed with one puff of 10 % lignocaine before introducing fiberoptic bronchoscope. Awake oral fiberoptic bronchoscopy attempted via the oral cavity aided by Berman airway, by continuous spray as you go technique with lignocaine spray 2%, Vocal cords identified and scope advanced till the carina, cuffed ETT no. 7 advanced. ETT tube was secured after confirmation with auscultation and ETco2 graph. Induction was done by giving intravenous Inj. Propofol 80 mg and Inj. Vecuronium 4 mg. Anesthesia was maintained with a mixture of oxygen, air, and sevoflurane with IPPV on volume AC mode. Intraoperatively Inj. Fentanyl 2 mcg/kg IV and Inj. Paracetamol 1gm IV given for analgesia. Patient was extubated uneventfully. She had a good post-op recovery and was discharged from the hospital.

### Discussion

In India, acid burns cases are becoming a major socioeconomic concern due to its immediate and long-term consequences on the affected person. In an observational study conducted by M. Singh et.al, on acid attack victims, they observed disfigurement of the face was seen in 100% of the victims, the ocular involvement was present in 78.8% of the cases, loss of hearing in 15.4% of cases, throat injuries in 9.6% of cases [5].

As most of the acid burn cases involves upper airway, in chronic cases due to the formation of scars and contractures difficult airway scenario is encountered. Post burn patients coming for surgery poses various challenges for anesthesiologist as it involves management of difficult airway and at same time understanding the psychological

need of the patient.

We had an old, blind hypertensive patient with chronic burns presenting with its own sets of airway related challenges. In this case, anesthetic challenges were difficult airway due to restricted mouth opening due to post acid-burns contracture, protruded teeth, difficult tracheostomy due to anatomical deformity because of burn contracture and skin grafting folds in front of neck. There was possibility of difficult mask ventilation due to deformed, narrow nasal airway with h/o nasal reconstructive surgery. Passage of nasal airway may result in injury and bleeding due to nasal fibrosis. Fiberoptic intubation through nasal route is considered easier than the oral route due to anatomical alignment, laryngeal opening is more easily seen with the fiberscope as it courses past the nasopharynx with less obstruction by the tongue [6]. In this case, we opted for oral route due to post burn fibrosis of nasal passage. Anesthesia risks were increased due to old age and hypertension. We did proper counselling of patients and allayed the anxiety of the procedure as her cooperation was important for the successful implementation of our procedure. We have given dexmedetomidine for providing sedation in a dose of 0.8 mcg/kg iv considering old age. Dexmedetomidine is a potent, highly selective  $\alpha$ -2 adrenoceptor agonist, with sedative, analgesic, anxiolytic, sympatholytic, and opioid-sparing properties. It provides a unique type of sedation, "conscious sedation", in which patients appear to be sleepy but are easily aroused, cooperative and communicative when stimulated without respiratory depression [7]. This property is helpful especially in awake fiberoptic intubation as in conscious patient there are less chances of desaturation and aspiration. Dexmedetomidine is pharmacologically unique in that the induced sedation involves activation of the endogenous sleep-promoting pathway [8]. In a case series report on difficult awake fiberoptic intubation by Sergio D. Bergese et.al, suggested that dexmedetomidine may be used as sole agent for Awake fiberoptic intubation, even in absence of topical anesthesia and provide stable hemodynamics [9]. We also had similar experience with dexmedetomidine and found it a useful drug for sedation and at same time maintaining the airway and hemodynamics. We observed that spray as you go technique greatly contributed in successful fiberoptic intubation by providing excellent anesthesia for the smooth passage of fiberoptic bronchoscope. In an interesting case study by K.A. Williams et.al, they combined nebulization and spray as you go topical local anesthesia on un-sedated human volunteers for awake fiberoptic intubation and found it to provide acceptable and good intubating condition for fiberoptic intubation. They also noted that a maximum calculated dose of lidocaine 9mg/kg did not produce toxic plasma concentrations of lidocaine [10]. In our case total dose of lidocaine did not exceeded 5mg/kg. Airway blocks were not given due to anatomical deformity and burns contractures. As our patient was blind and old, we visited her and made good rapport with her preoperatively which helped us to do awake fiberoptic intubation.

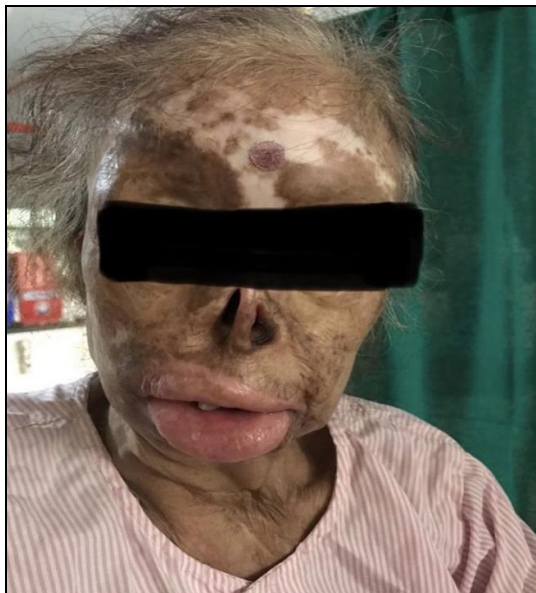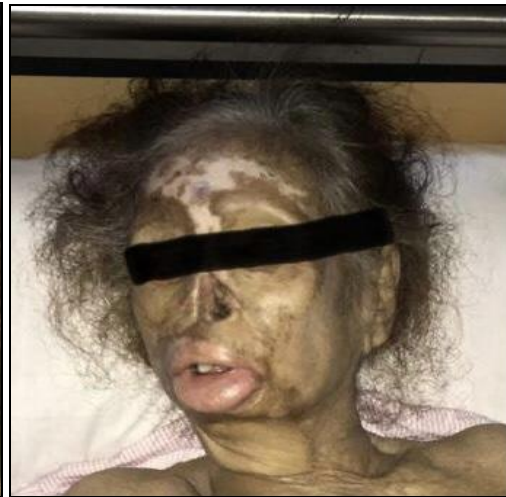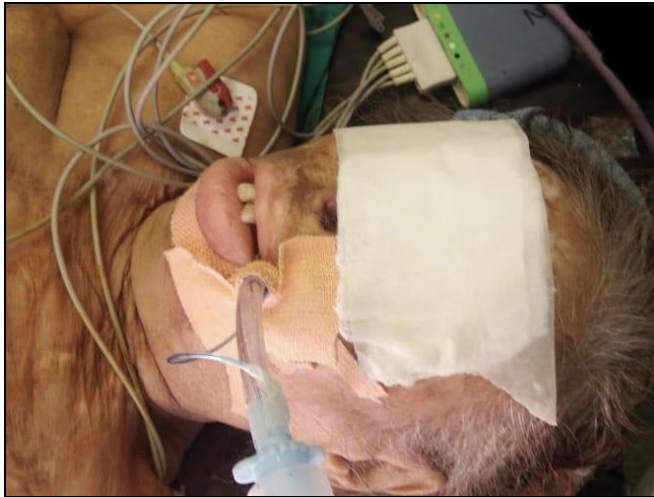
Other methods used in difficult airway scenario is video laryngoscopy which helps in visualization of laryngeal structure with limited neck movement and aid in intubation in patients with MO >3 cm and mild to moderate contracture neck [11].

The airway related complications have significantly decreased due to better knowledge, skills of anesthesiologist and widespread use of newer airway gadgets like video laryngoscopes and fiberoptic bronchoscopes. In this case proper planning, counselling, topical application of lignocaine 2% with advantage of conscious sedation resulted in successful fiberoptic intubation. We recommend the use of spray as you go technique with conscious sedation with dexmedetomidine for awake fiberoptic intubation.

### Conclusion

Most airway problems can be solved with available gadgets and techniques, but clinical judgment borne of experience and expertise is crucial in implementing the skills in management of difficult airway. Meticulous planning, perioperative counselling, adequate sedation with dexmedetomidine and spray as you go technique facilitates fiberoptic intubation in difficult airway scenario.

**Conflict of interest:** None.



### References

1. Costa Santos D, Barros F, Frazao M, Maia M. Pre-burn centre management of the airway in patients with face burns. *Ann Burns Fire Disasters* 2015;28(4):259-263.
2. Jehan El Kholy, Nashwa Nabil Mohamed. A case report of successful awake fiberoptic intubation in a child with severe airway burn, *Egyptian Journal of Anaesthesia* 2013;29(2):171-174.
3. Ahmad I, El-Boghdadly K, Bhagrath R, Hodzovic I, McNarry AF, Mir F, *et al.* Difficult Airway Society guidelines for awake tracheal intubation (ATI) in adults. *Anaesthesia* 2020;75(4):509-528.
4. Xue FS, Liu HP, He N, Xu YC, Yang QY, Liao X, *et al.* Spray-as-you-go airway topical anesthesia in patients with a difficult airway: a randomized, double-blind comparison of 2% and 4% lidocaine. *Anesth Analg* 2009;108(2):536-43.
5. Singh M, Kumar V, Rupani R, Kumari S, Shiuli, Yadav PK, *et al.* Acid attack on women: A new face of gender-based violence in India. *Indian J Burns* 2018;26(1):83-86.
6. Stephen Collins R, Randal Blank S. Fiberoptic Intubation: An Overview and Update. *Respiratory Care* 2014;59(6):865-880.
7. Afonso J, Reis F. Dexmedetomidine: current role in anesthesia and intensive care. *Rev Bras Anesthesiol* 2012;62(1):118-133.
8. Nelson LE, Lu J, Guo T, Saper CB, Franks NP, Maze M. The alpha2-adrenoceptor agonist dexmedetomidine converges on an endogenous sleep-promoting pathway to exert its sedative effects. *Anesthesiology* 2003;98(2):428-436.
9. Bergese SD, Khabiri B, Roberts WD, Howie MB, McSweeney TD, Gerhardt MA. Dexmedetomidine for conscious sedation in difficult awake fiberoptic intubation cases. *J Clin Anesth* 2007;19(2):141-144.
10. Williams KA, Barker GL, Harwood RJ, Woodall NM. Combined nebulization and spray-as-you-go topical local anaesthesia of the airway. *Br J Anaesth* 2005;95(4):549-53.
11. Gupta R, Sahni A. Is video laryngoscopy easier than direct laryngoscopy for intubation in patients with contracture neck. *Saudi J Anaesth* 2020;14(2):206-211.